

ANP1107: Topic #5 - The Anatomy and Physiology of the Male and Female Reproductive Systems (Chapters 27 & 28)

*What are the **purposes** of the male and female reproductive systems?*

*What do you need to already understand **before** approaching the anatomy and physiology of the male and female reproductive systems?*

*The female system is **cyclical** whereas the male system is not. What does this really mean? What important differences will allow one system to be cyclical and the other to maintain fairly steady production of hormones and gametes?*

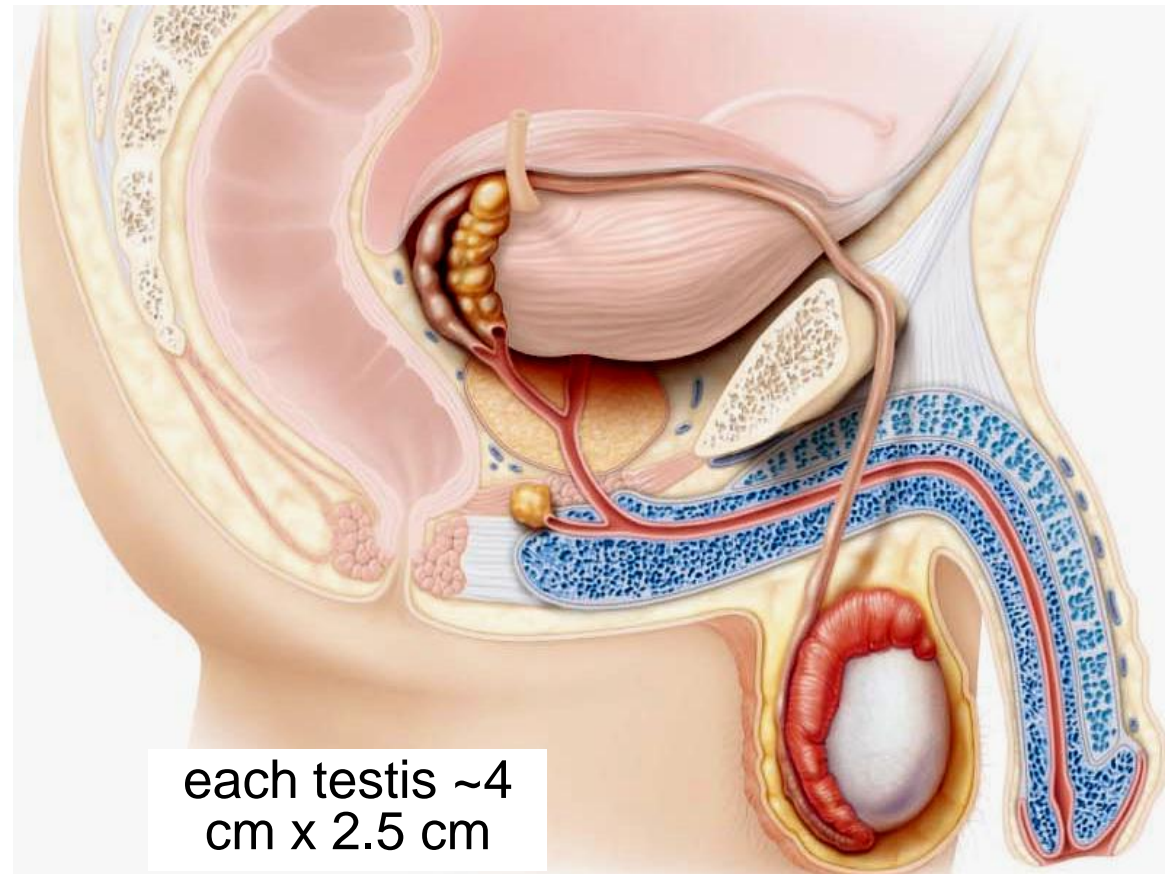
5.1 Describe the anatomy of the male reproductive system

5.1.1 describe the gross & microscopic anatomy of the testes

- testes located in **scrotum**: sac of skin + superficial fascia outside abdominopelvic cavity at root of penis
 - sparse hairs, more heavily pigmented
- midline **septum** provides one compartment/testis
- exterior position provides essential (*why?*) temp 3⁰ C **lower** than core

What are the roles of the **dartos** & **cremaster** muscles in testicular temperature regulation?

Fig. 27.1

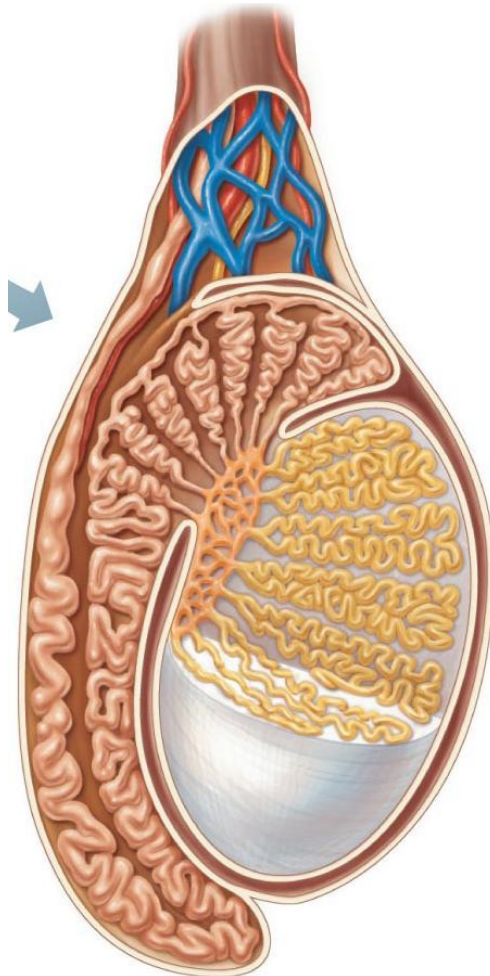


each testis ~4
cm x 2.5 cm

2 tunics:

- (i) **Tunica vaginalis:** outer, 2-layered (derived from?.....)
- (ii) **Tunica albuginea:** fibrous capsule of testis (white coat); septal extensions divide each testis into 250-300 wedge-shaped lobules

each lobule = 1 to 4 coiled
seminiferous tubules



J. Carnegie, UofO

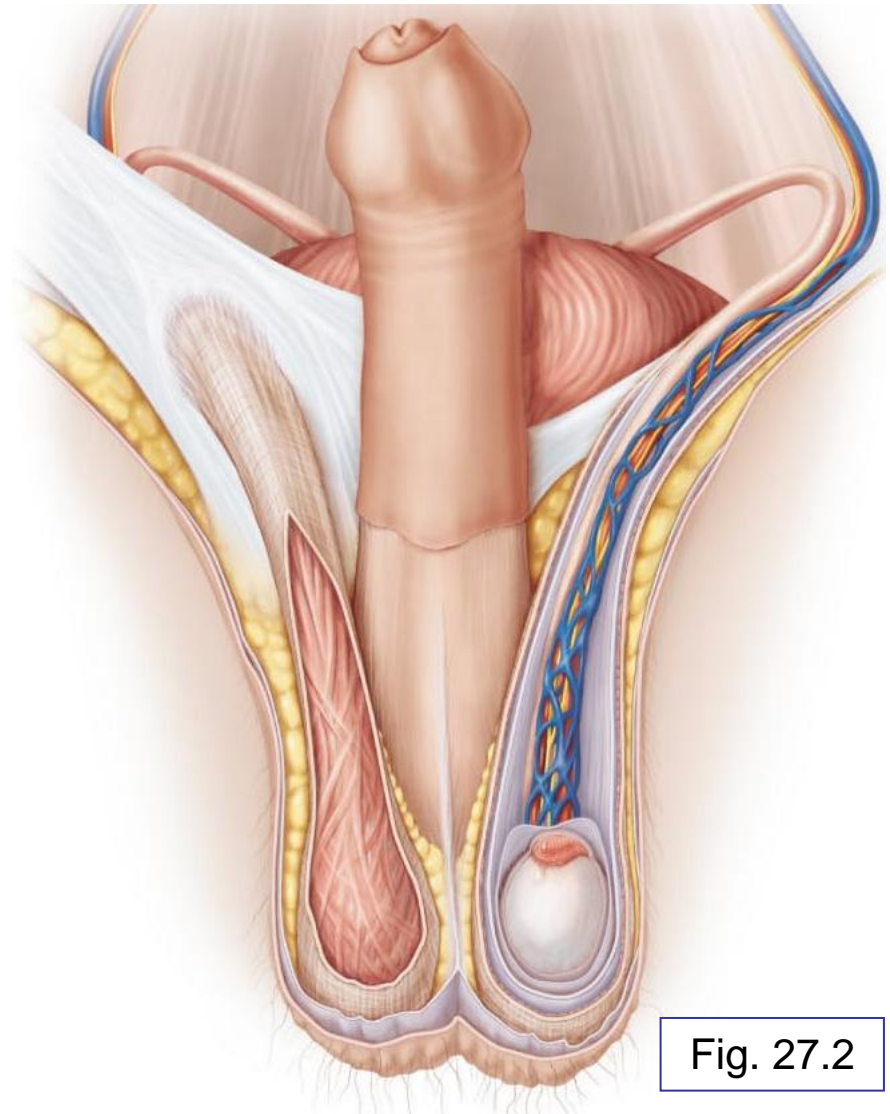
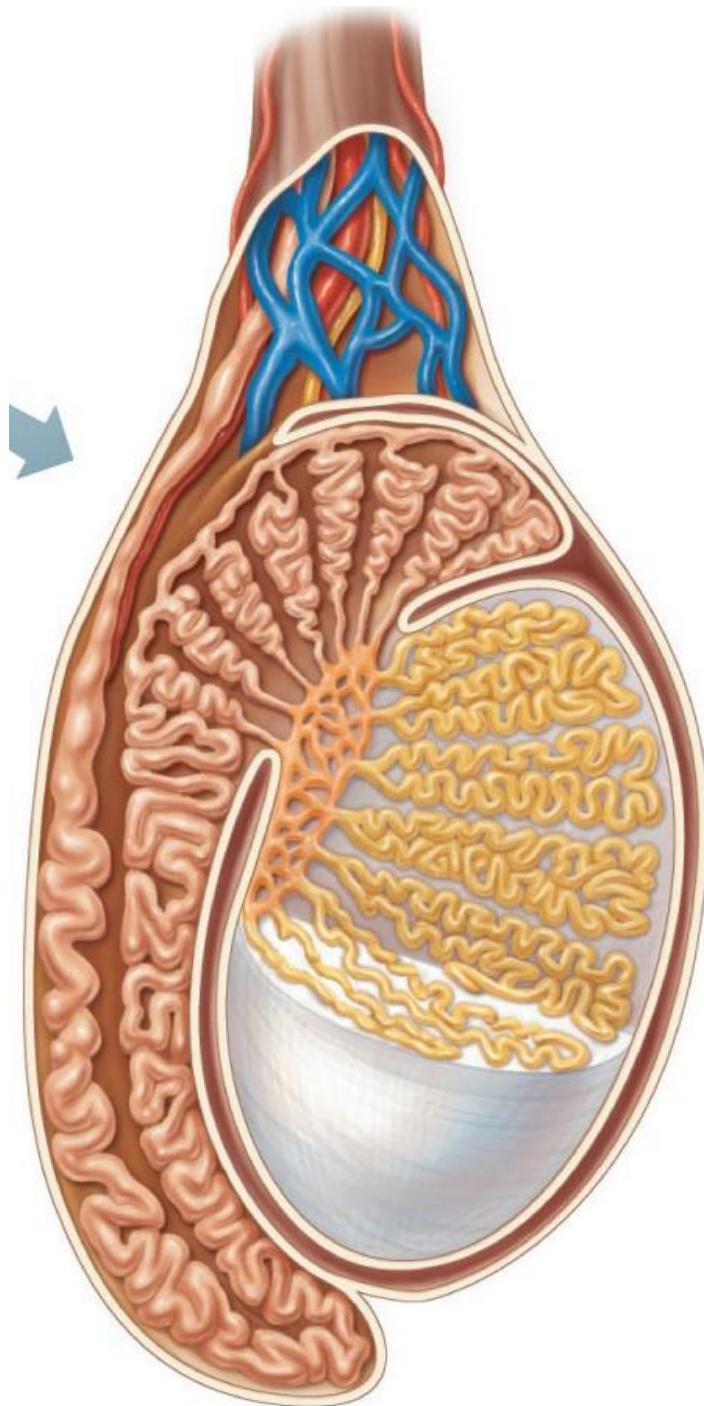


Fig. 27.2



seminiferous tubules (1)



tubulus rectus (2)



rete testes (3)



efferent ductules (4)



epididymis (5)

Fig. 27.3a

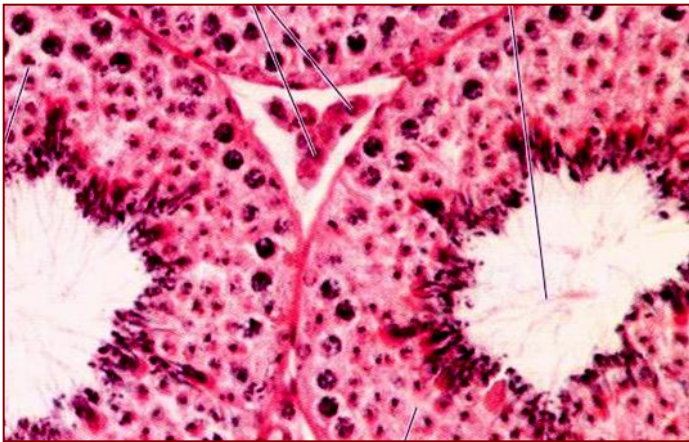Leydig Cells

interstitial cells that produce androgens (testosterone)

Interstitial means what??

Blood Supply

- testicular arteries (branch from abdominal aorta)
- testicular veins form pampiniform plexus (*role?*)
- spermatic cord: blood & lymph vessels, nerves, vas deferens



Where are the Leydig cells?

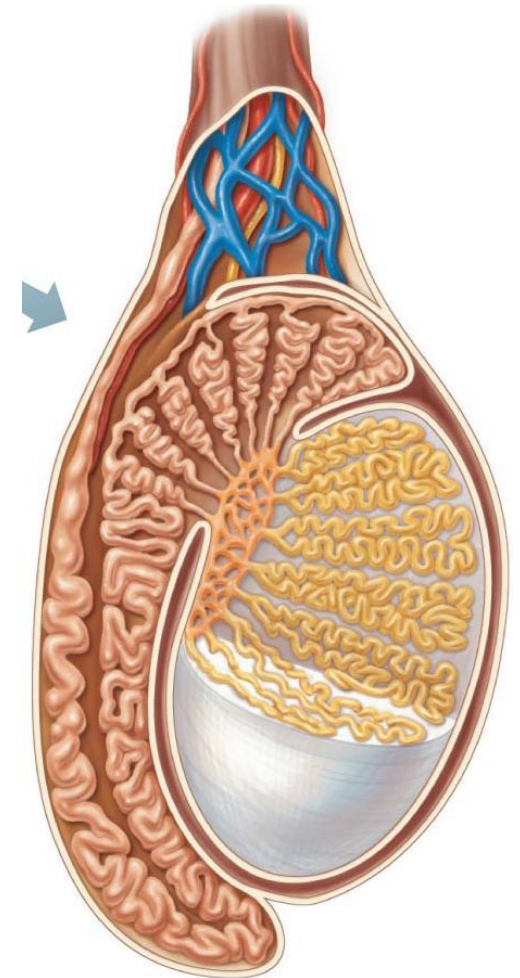


Fig. 27.3a

5.1.2 describe in detail the pathway followed by sperm from the epididymis to the exterior of the body

A. Epididymis (~3.8 cm)

- **head** caps superior part of testis (receives sperm from ??)
- **body** & **tail** contain highly coiled duct of epididymis ;(uncoiled = ~6 m!)
- sperm that enter epididymis are **immature, nonmotile**
- ~20 days to traverse epididymis → gain ability to swim

What happens to the epididymis during ejaculation?

What happens to sperm that do not get ejaculated for a long period of time?

How long can sperm be stored in the epididymis?

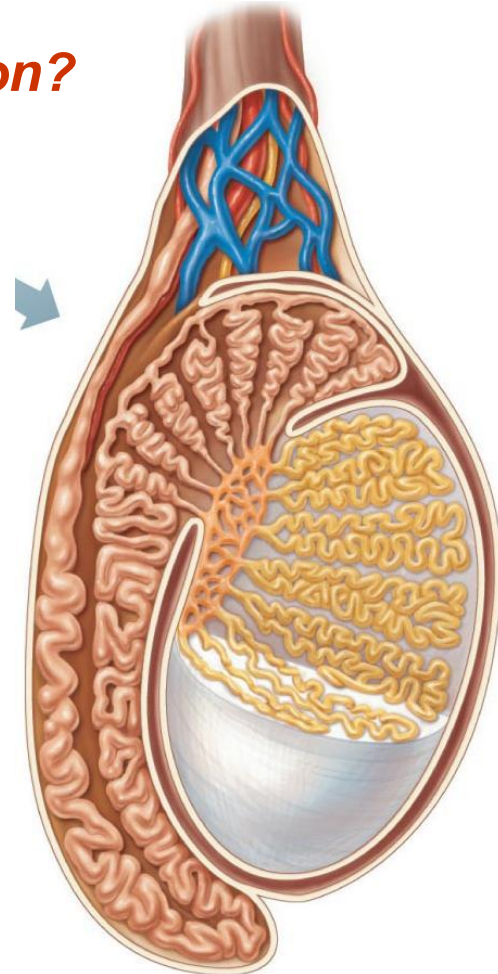


Fig. 27.3a

B. Ductus (Vas) Deferens (1/testis)

- ~45 cm long
- describe the pathway taken by the vas deferens to the point where it becomes the ejaculatory duct
 - ejaculatory duct passes into prostate gland, then into urethra
 - each vas deferens propels sperm out during ejaculation
- What is a vasectomy? Are there any risks associated with this procedure?

C. The Urethra

- terminal portion, serves both urinary & reproductive functions

1) what is the *prostatic urethra*?

2) what is the *membranous urethra*?

3) what is the *spongy (penile) urethra*?

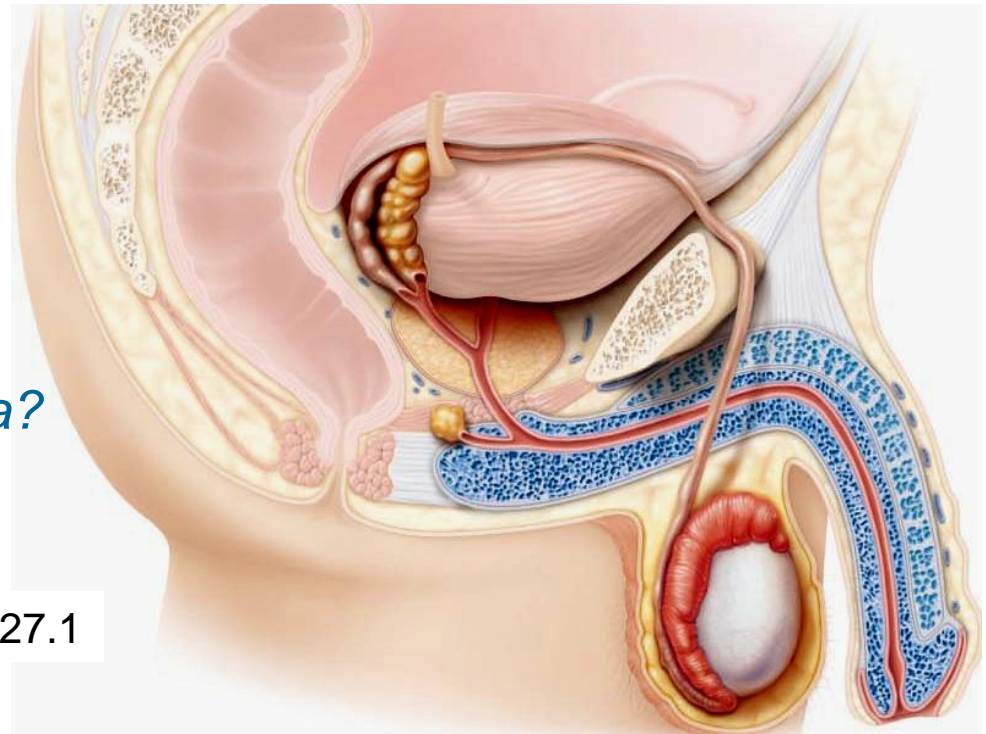


Fig. 27.1

5.1.3. Localize & describe the structure of the male reproductive accessory glands

- produce secretions that, along with sperm, make up **semen**

A. Seminal Vesicles (2)

- posterior wall of bladder; about size & shape of little finger
- contribute ~60% of semen volume (yellow, viscous, alkaline; fructose, ascorbic acid, coagulating enzyme, prostaglandins)
- sperm + seminal fluid in **ejaculatory duct**

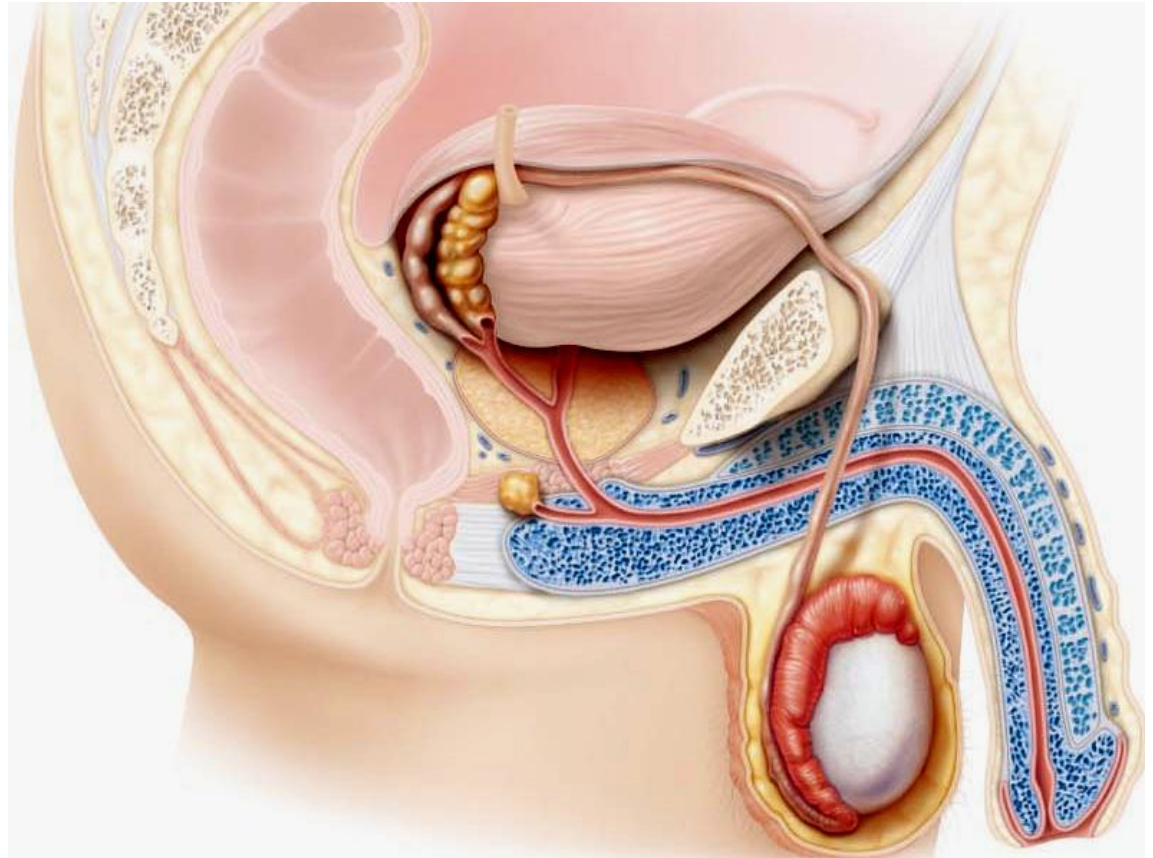


Fig. 27.1

B. Prostate Gland (1)

single gland, size & shape of chestnut; encircles urethra inferior to bladder

milky secretion (~1/3 semen volume; contains enzymes; role in activating sperm)

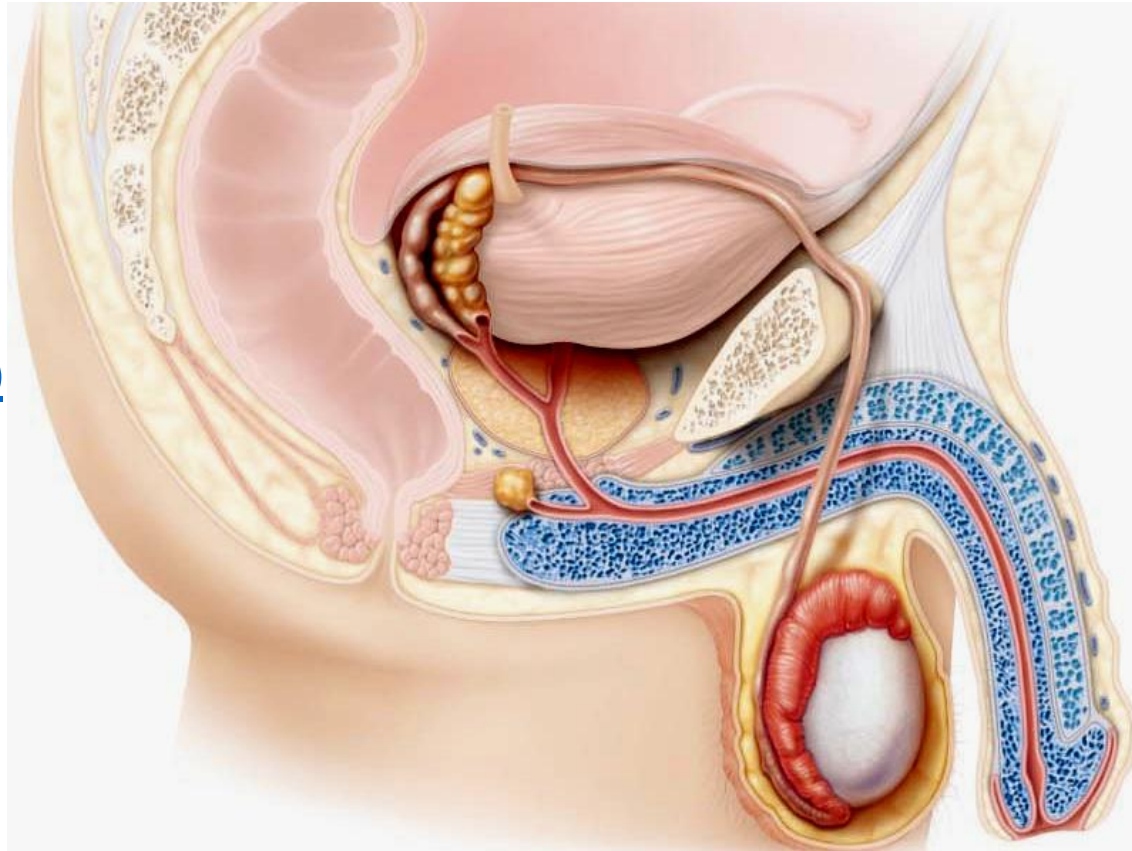
secretion to prostatic urethra via several ducts during ejaculation

C. Bulbourethral Glands (2)

pea-sized, inferior to prostate
thick, clear mucus to spongy
urethra before ejaculation

(purpose??)

Fig. 27.1



5.1.4 describe the structural organization of the penis as a copulatory organ

delivers sperm into ♀ reprod tract

external genitalia = penis + scrotum

penis = attached **root** + free **shaft** or body; enlarged tip = **glans penis**

foreskin or **prepuce** = cuff of skin around glans (**circumcision**)

internally, penis contains:

(i) **spongy urethra**

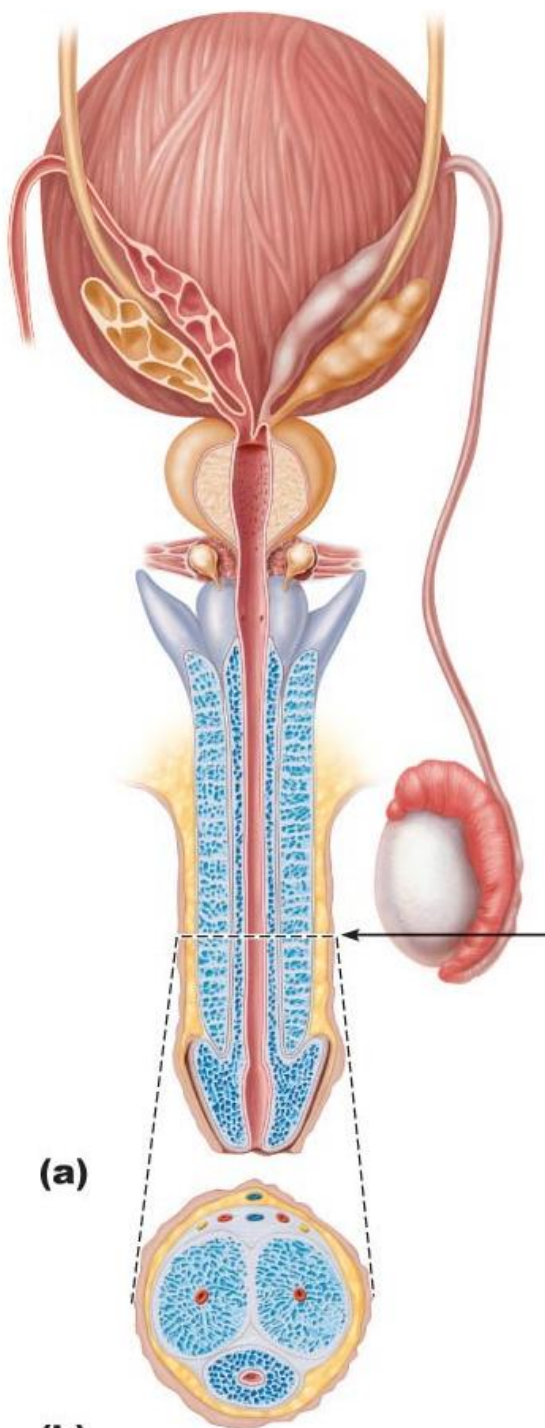
(ii) 3 **corpora** of erectile tissue

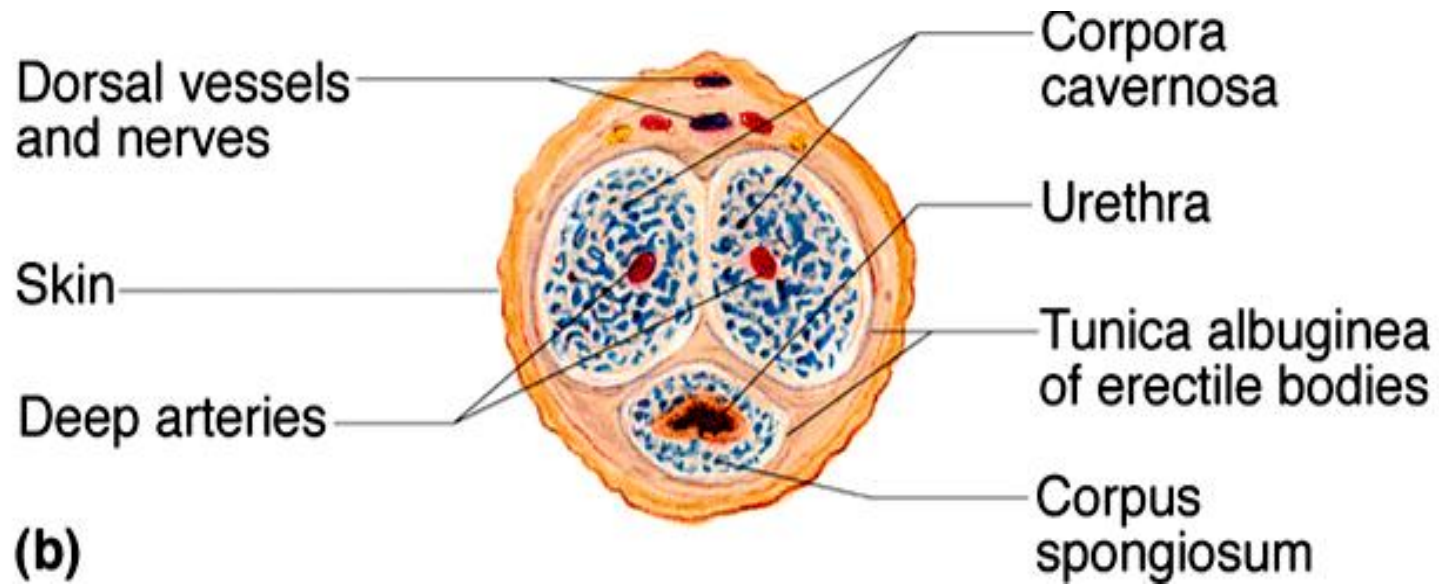
2 **corpora cavernosa**

1 midventral **corpus spongiosum**

(expands distally ➤ **glans**; proximally, expands ➤ **bulb** of penis)

Fig. 27.4





5.1.5 describe the composition of semen

secretions provide:

- (i) transport medium
- (ii) nutrients (eg: fructose)
- (iii) chemicals (eg: PGs) -protect/activate sperm

- pH 7.2-7.6 neutralizes pH 3.5-4 of vagina

SEMEN: 2-5 ml/ejaculation;
[sperm] = 50-100 million/ml

Semen Analysis

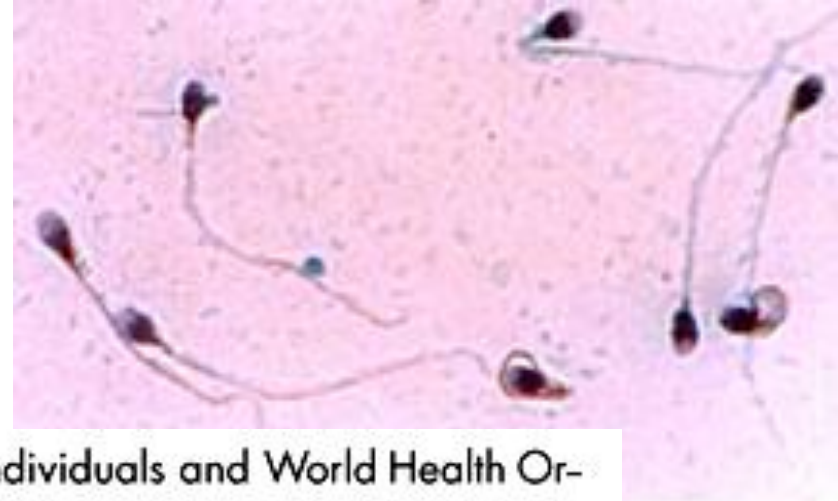

Table 1. Semen characteristics among 500 fertile individuals and World Health Organization (WHO) reference values

Variable	Average and standard deviation	Percentile			WHO reference values ⁶	Proportion of individuals with results below WHO reference values (%) ⁶
		25	50	75		
Semen volume (ml)	2.75 ± 1.43	1.6	2.5	3.7	≥ 2.0	32.2
Sperm concentration x 10 ⁶ /ml	99.55 ± 61.11	51.9	87.2	147.4	≥ 20 x 10 ⁶ /ml	6.0
Total number of spermatozoa	283.74 ± 235.41	118.0	225.0	373.0	≥ 40 x 10 ⁶ /ml	7.8
Sperm progressive motility (a + b) (%)	58.65 ± 18.26	47.0	61.0	72.0	≥ 50%	29.6
Normal sperm morphology (%)	17.57 ± 9.50	11.0	16.0	24.0	≥ 30%	87.2

Key Choices:

a) bulbourethral glands

b) epididymis

c) ductus (vas) deferens

d) glans penis

e) penis

f) prepuce

g) prostate gland

h) seminal vesicles

i) scrotum

j) spermatic cord

k) testes

l) urethra

-
- _____ 1. Organ that delivers semen to the ♀ reproductive tract.
- _____ 2. Site of sperm & testosterone production.
- _____ 3. Passageway for sperm from epididymis to ejaculatory duct.
- _____ 4. Conveys both sperm & urine down length of the penis.
- _____ _____ 5. Organs that contribute to the formation of semen.
- _____ _____
- _____ 6. External sac that houses the testes.
- _____ 7. Tubular storage site for sperm; hugs lateral aspect of testes.
- _____ 8. Cuff of skin encircling the glans penis.
- _____ 9. Surrounds the urethra at the base of bladder; produces a milky, alkaline secretion.
- _____ 10. Produces over half of the seminal fluid.
- _____ 11. Empties a lubricating mucus into the urethra
- _____ 12. CT sheath enclosing vas deferens, blood vessels & nerves



5.2 Describe the regulation of male reproductive function

5.2.1 differentiate functionally between Sertoli & Leydig cells

- normal rate of sperm production is 2×10^8 sperm/day
- testis is a source of both **germ cells & hormones**
- testis is composed of:

(i) **seminiferous tubules**: = **Sertoli** cells + **spermatogenesis intermediates**; 80% of testicular mass

(ii) **Leydig** cells: synthesize androgens (**testosterone**)

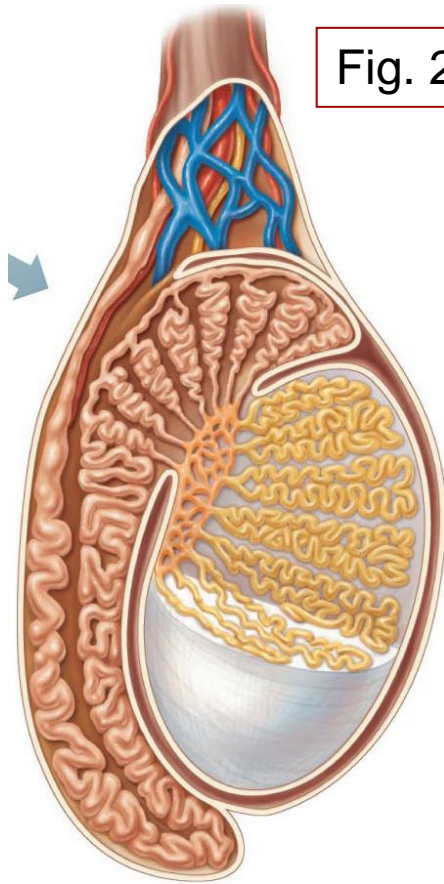
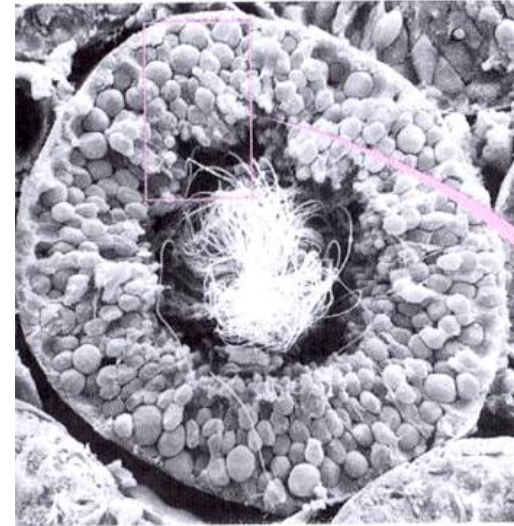


Fig. 27.3a

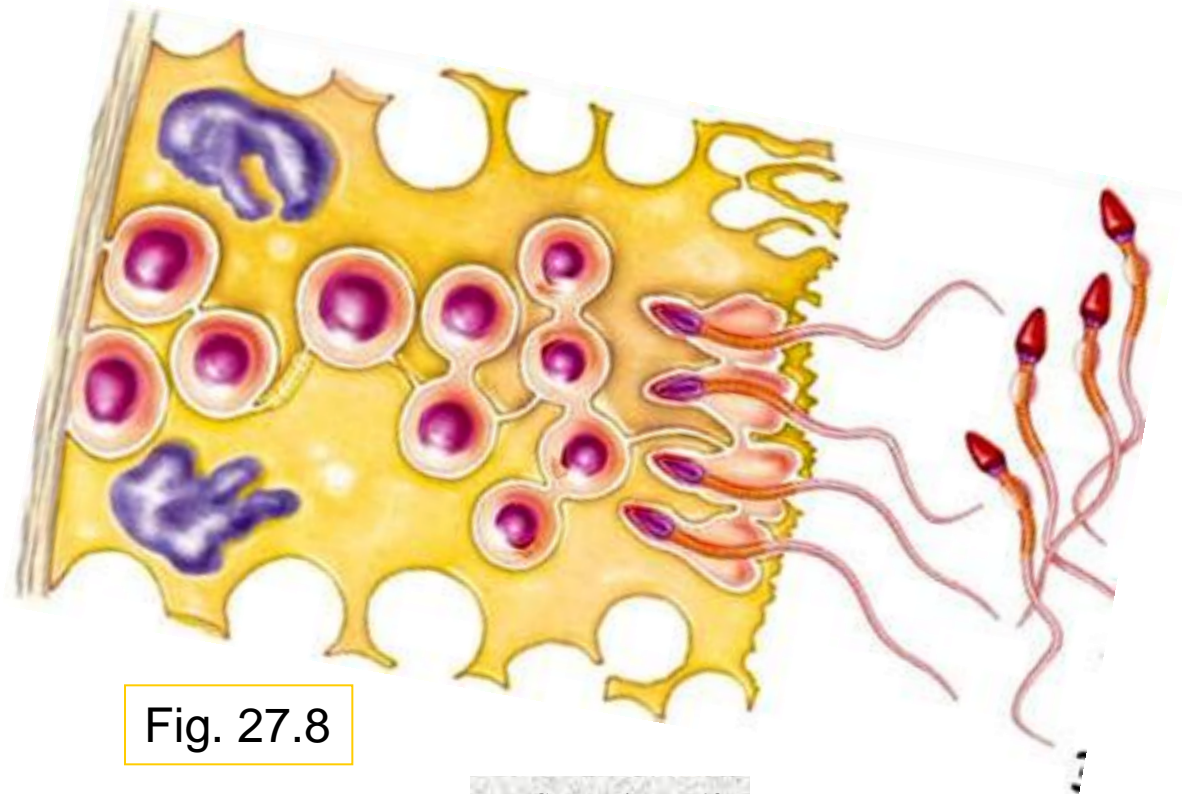
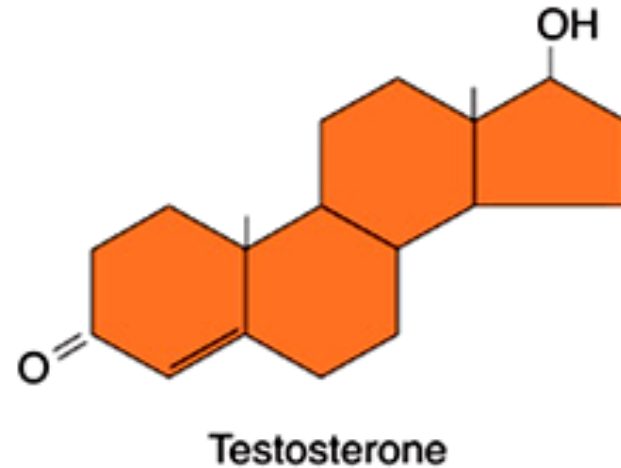
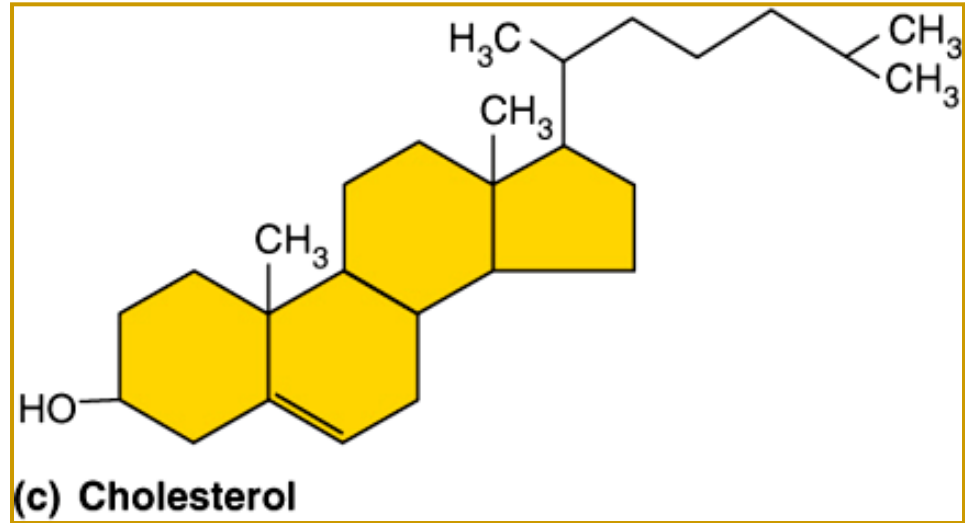
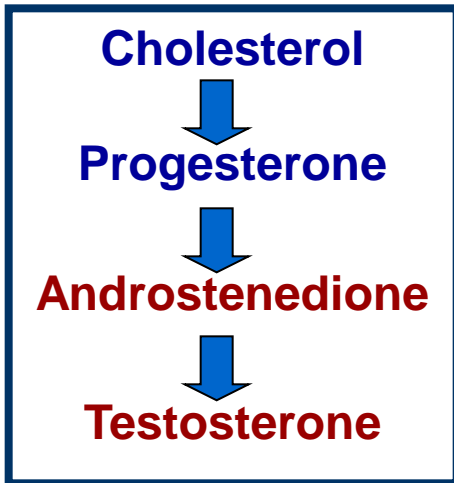


Fig. 27.8

5.2.2 distinguish steroid hormones (both structurally and functionally) from amino acid-based hormones

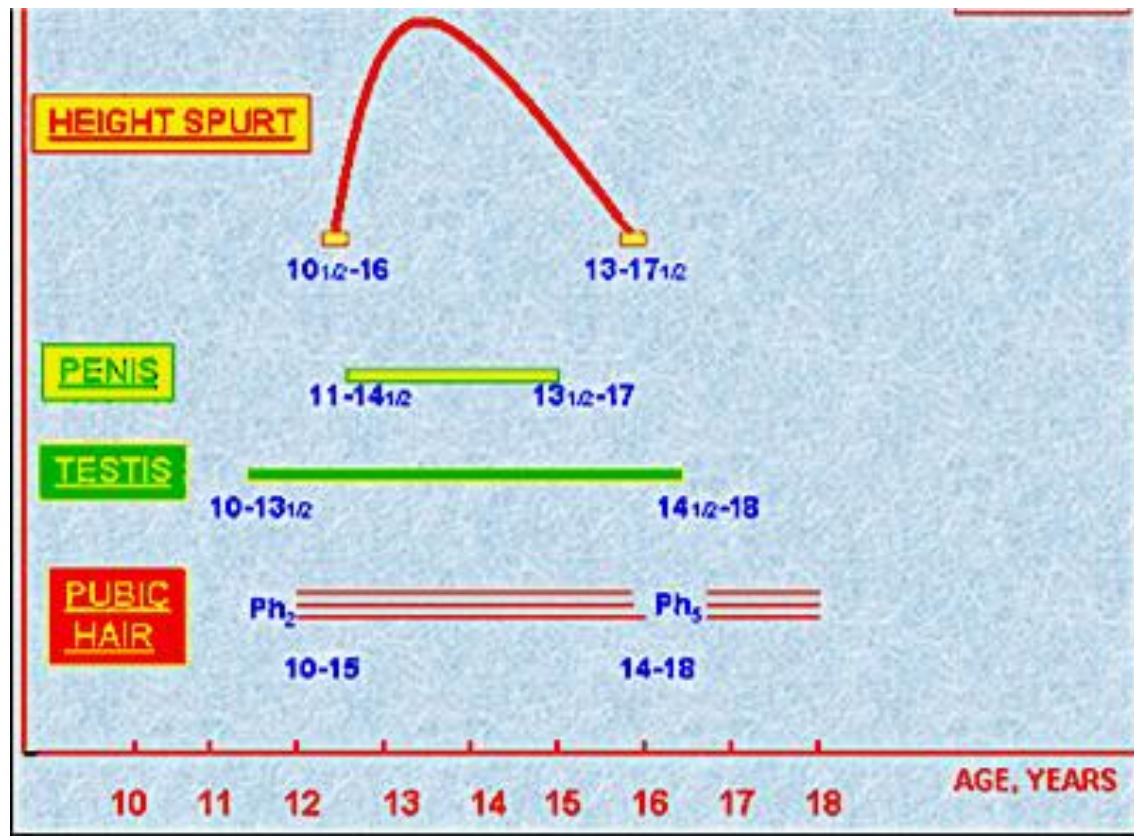


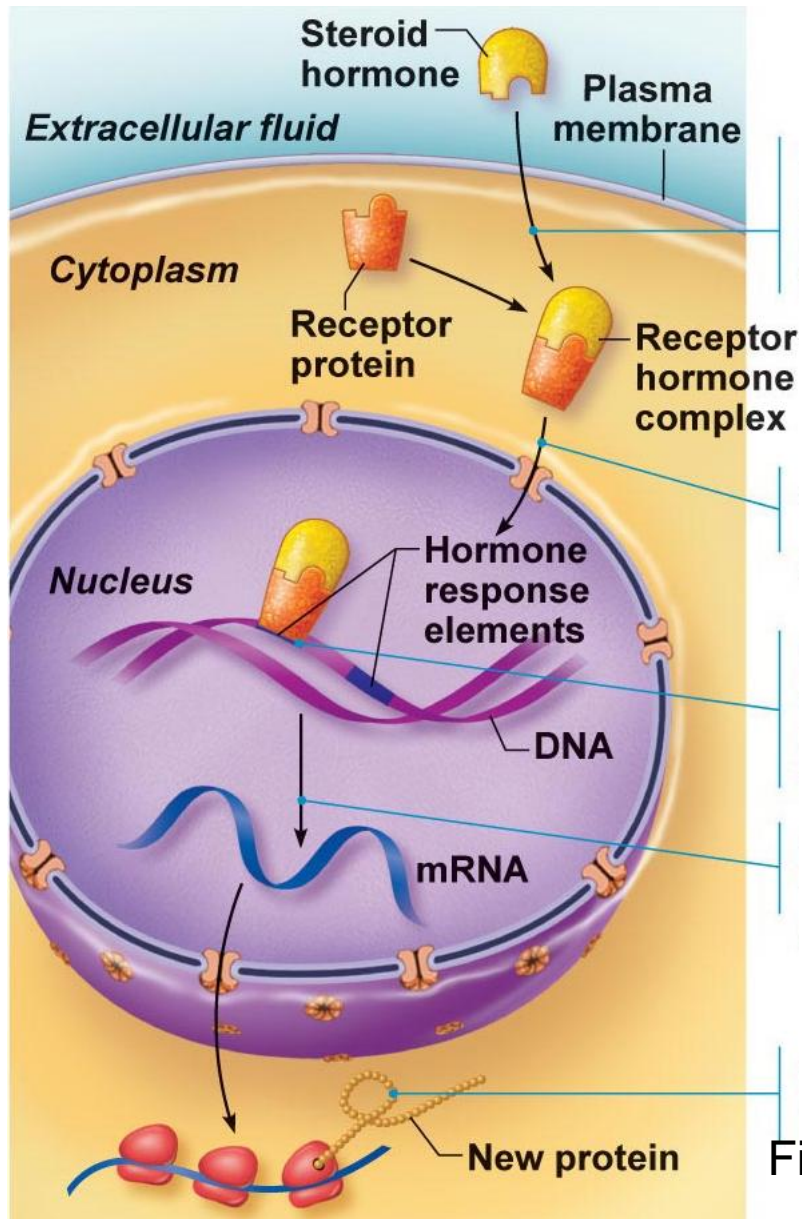
What cell type in testis synthesizes testosterone?

Actions of testosterone:

- gonadal:** (i) growth/maturation of gonads & accessory organs (puberty)
(ii) essential for spermatogenesis
- somatic:** (i) adolescent growth spurts (start & stop - how???)
(ii) growth of larynx & vocal cords
(iii) secretion of sweat
(iv) hair (face, chest, armpits, groin)
- metabolic:** (i) anabolic: hematopoiesis, BMR
- CNS:** (i) maintenance of libido
(ii) aggression

Which of these events begins first?





steroid hormones are **lipids** - *significance in terms of their interaction with cells??*

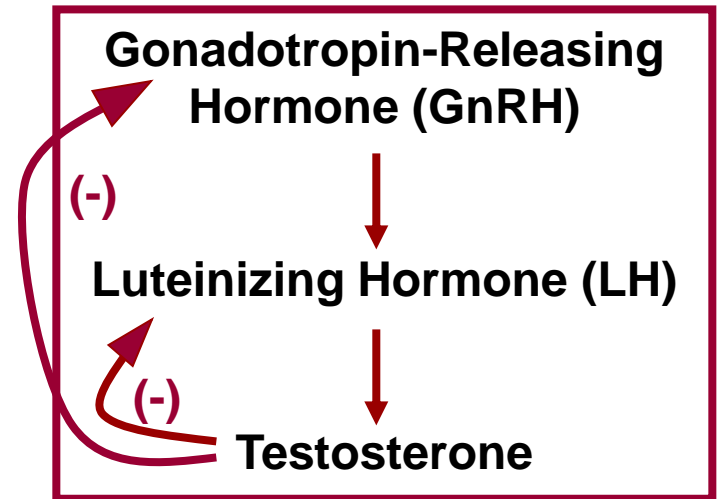


Fig. 16.3

testosterone synthesis stimulated by LH (luteinizing hormone) from the anterior pituitary

5.2.3 describe the hypothalamic & pituitary regulation of steroidogenesis in the male

Anterior Pituitary Hormones:

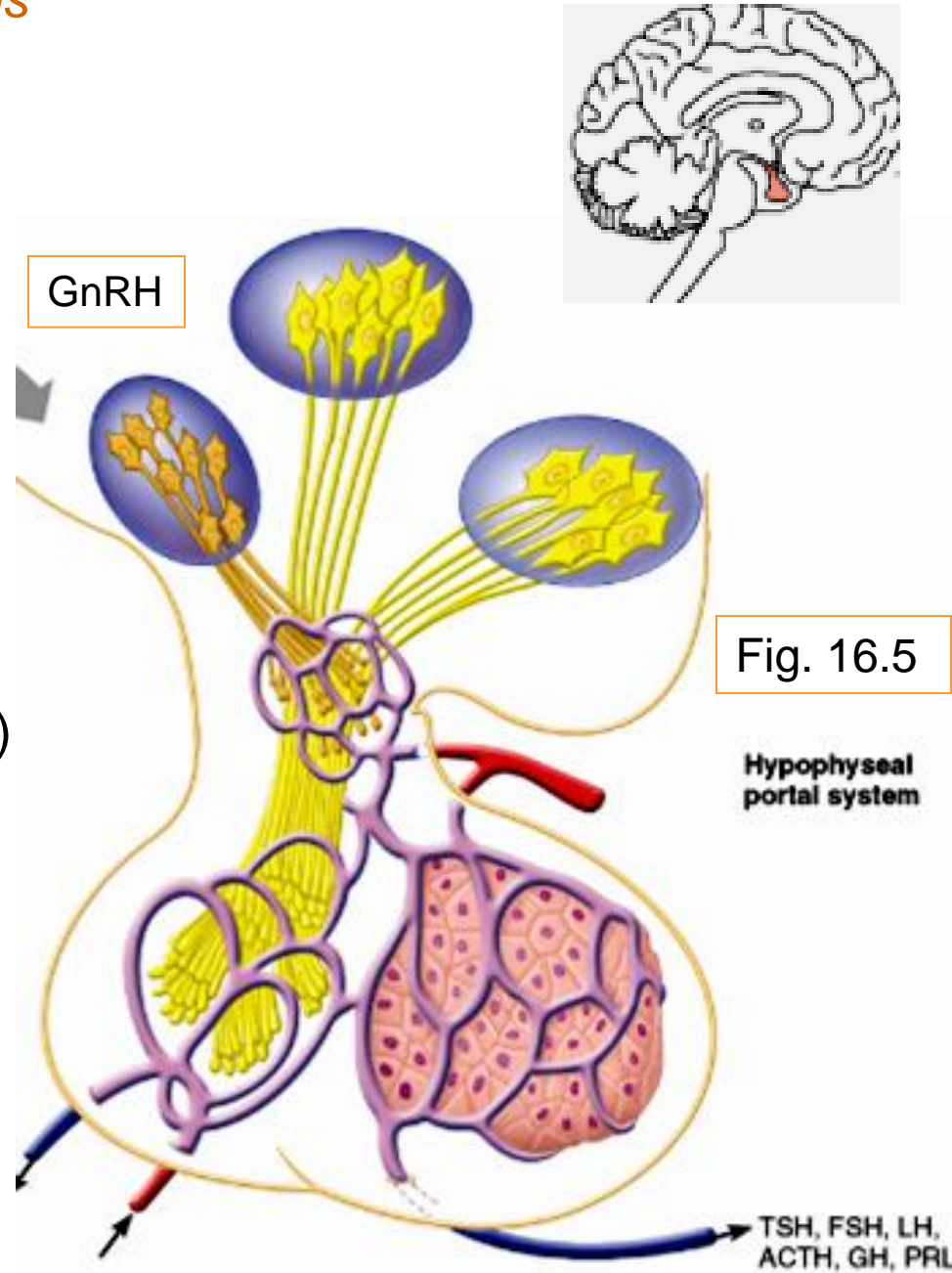
- **gonadotropins** are glycoproteins
- **water-soluble** – significance?
 - cell surface receptors; 2nd messengers
 - > regulate activity of enzymes

Follicle Stimulating Hormone (FSH)

stimulates Sertoli cells to support spermatogenesis (T required)

Luteinizing Hormone (LH)

stimulates Leydig cells to secrete testosterone



GnRH: Gonadotropin Releasing Hormone
pulsatile secretion by **hypothalamic**
neurons

stimulates secretion of FSH & of LH

Inhibin: released by **Sertoli** cells
inhibits secretion of **ONLY FSH**

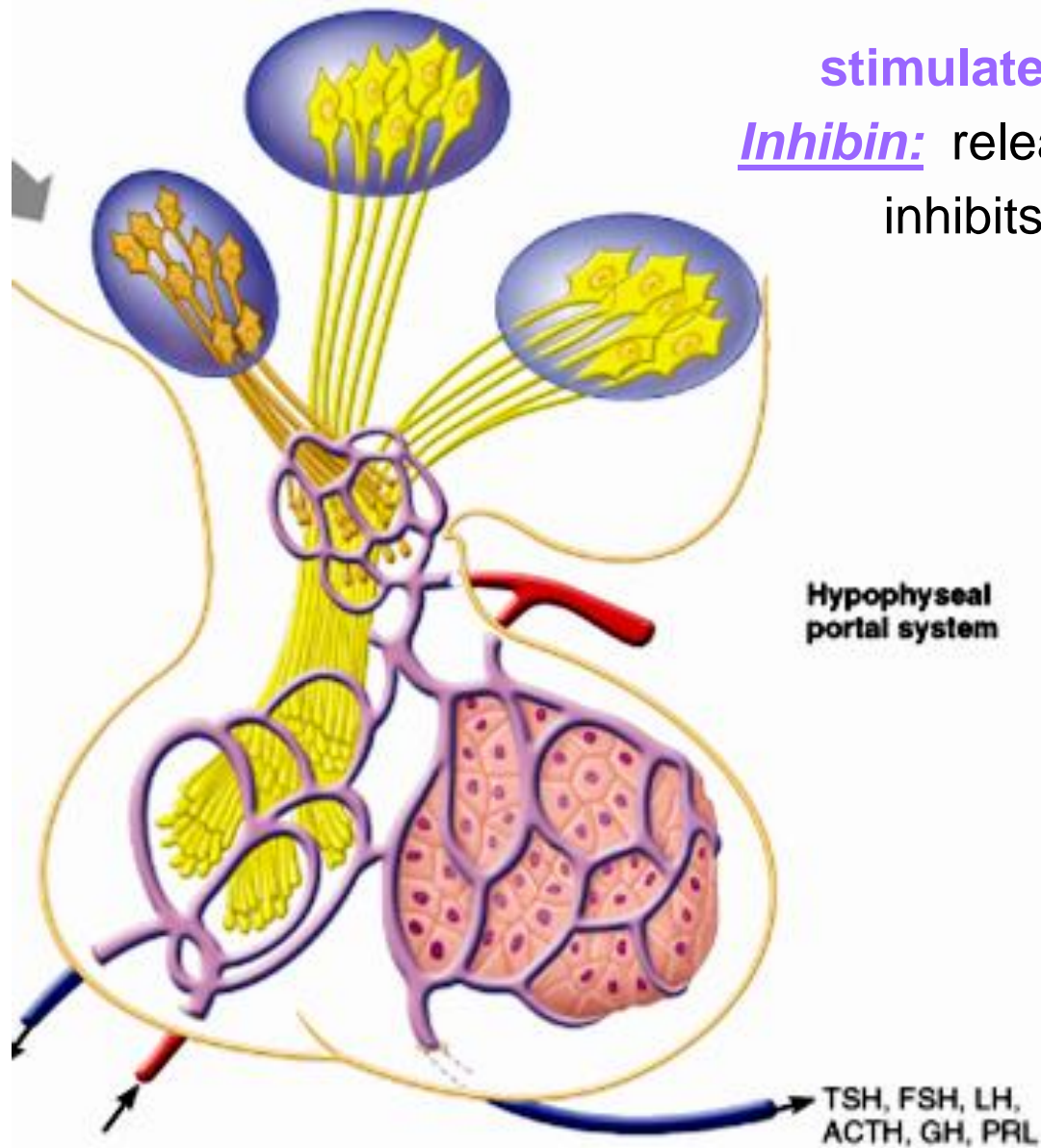


Fig. 16.5

5.2.4 outline the main steps in spermatogenesis

- starting point is **spermatogonium [diploid]**
 - at puberty, 6×10^6 spermatogonia per testis; self-perpetuating
- What does this mean??*

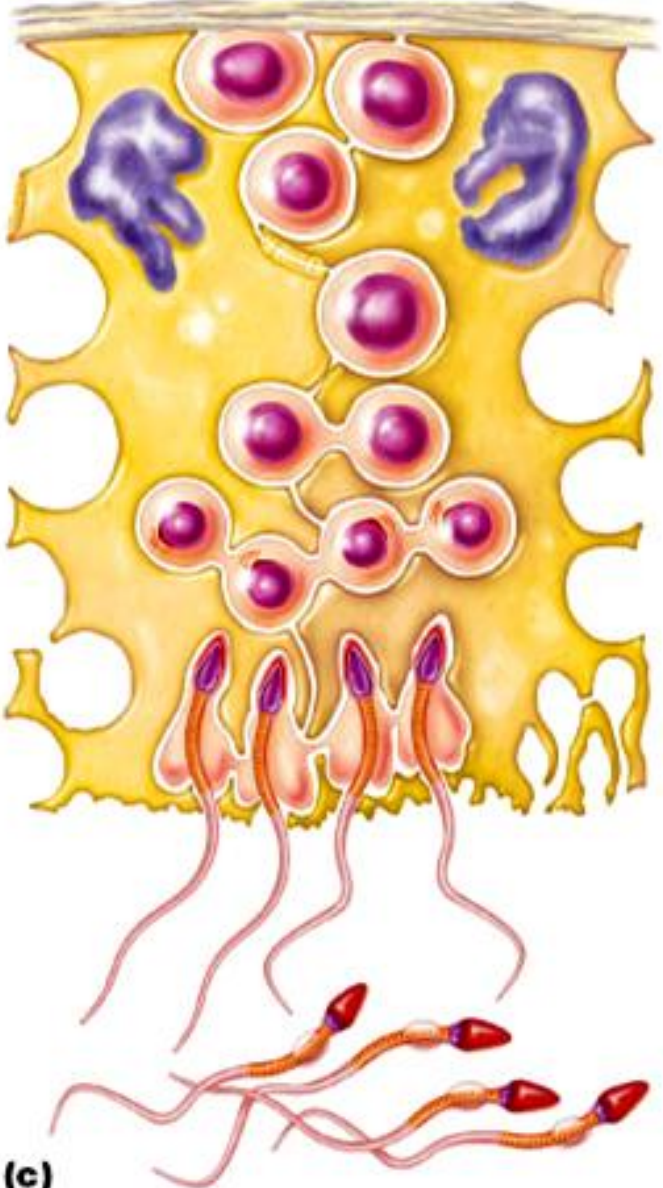
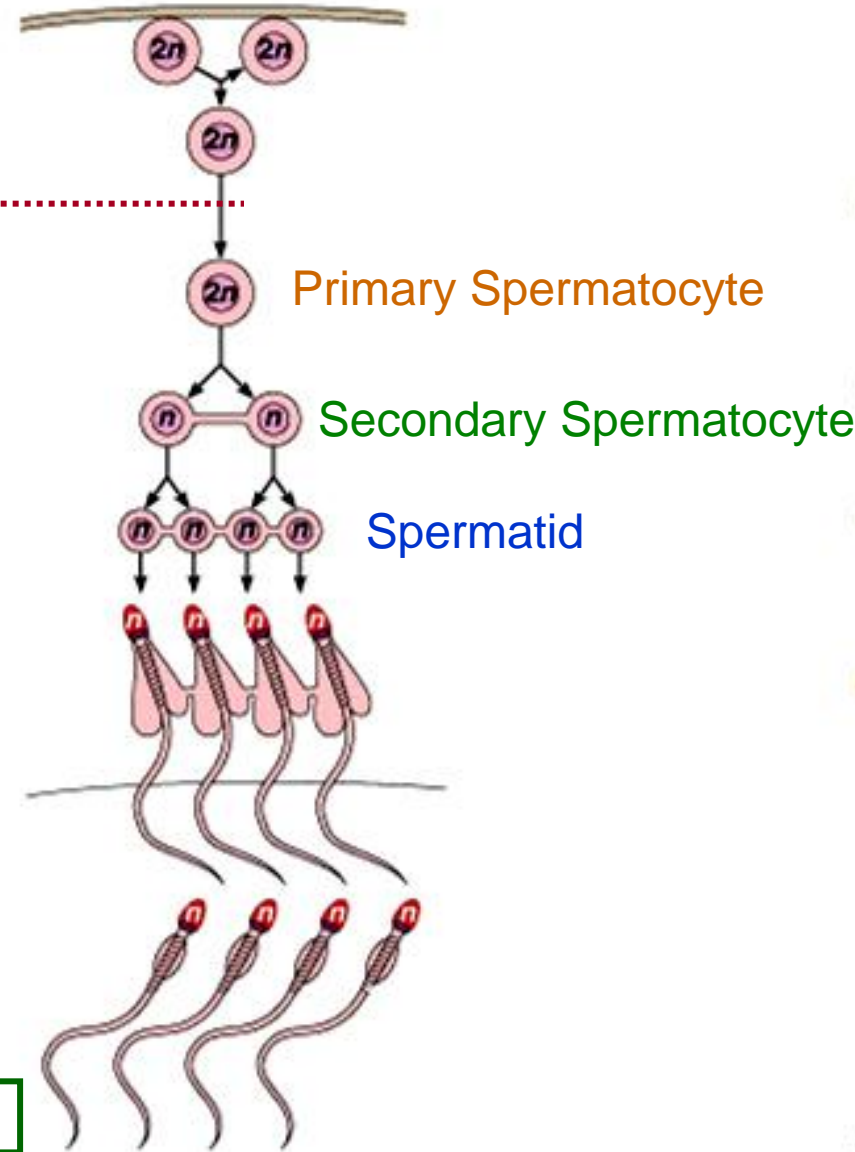


Fig. 27.7

From Spermatogonium to Spermatozoan

(i) Spermatogonium: (2N)

- starting point; supply constantly maintained
- first step: spermatogonium B undergoes 2 mitotic divisions → 4 1^0 spermatocytes

(ii) Primary Spermatocyte (2N)

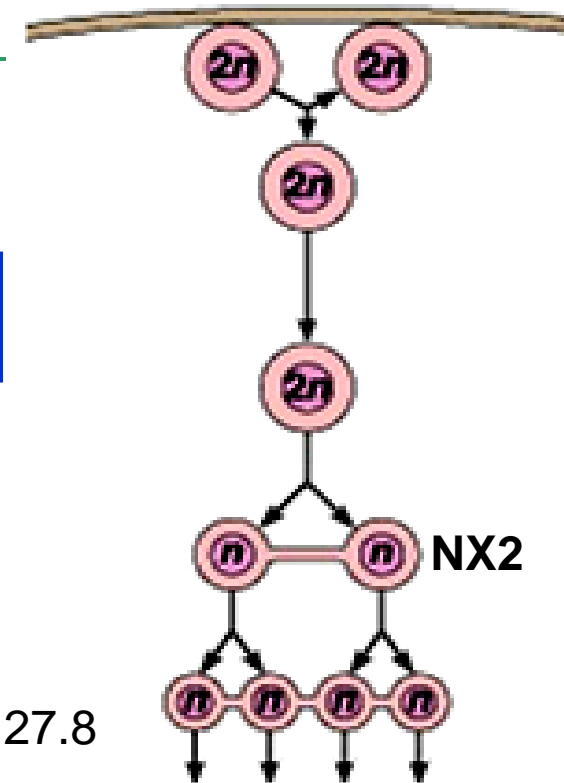
- starting point of meiotic divisions
- first round yields 2 **secondary spermatocytes**/primary spermatocyte

(iii) Secondary Spermatocyte:

- **N x 2**: 2 copies of each of 23 chromatids (eg: if ♂, would have 2 Y chromatids)
- 2nd division → 2 haploid (N) **spermatids**

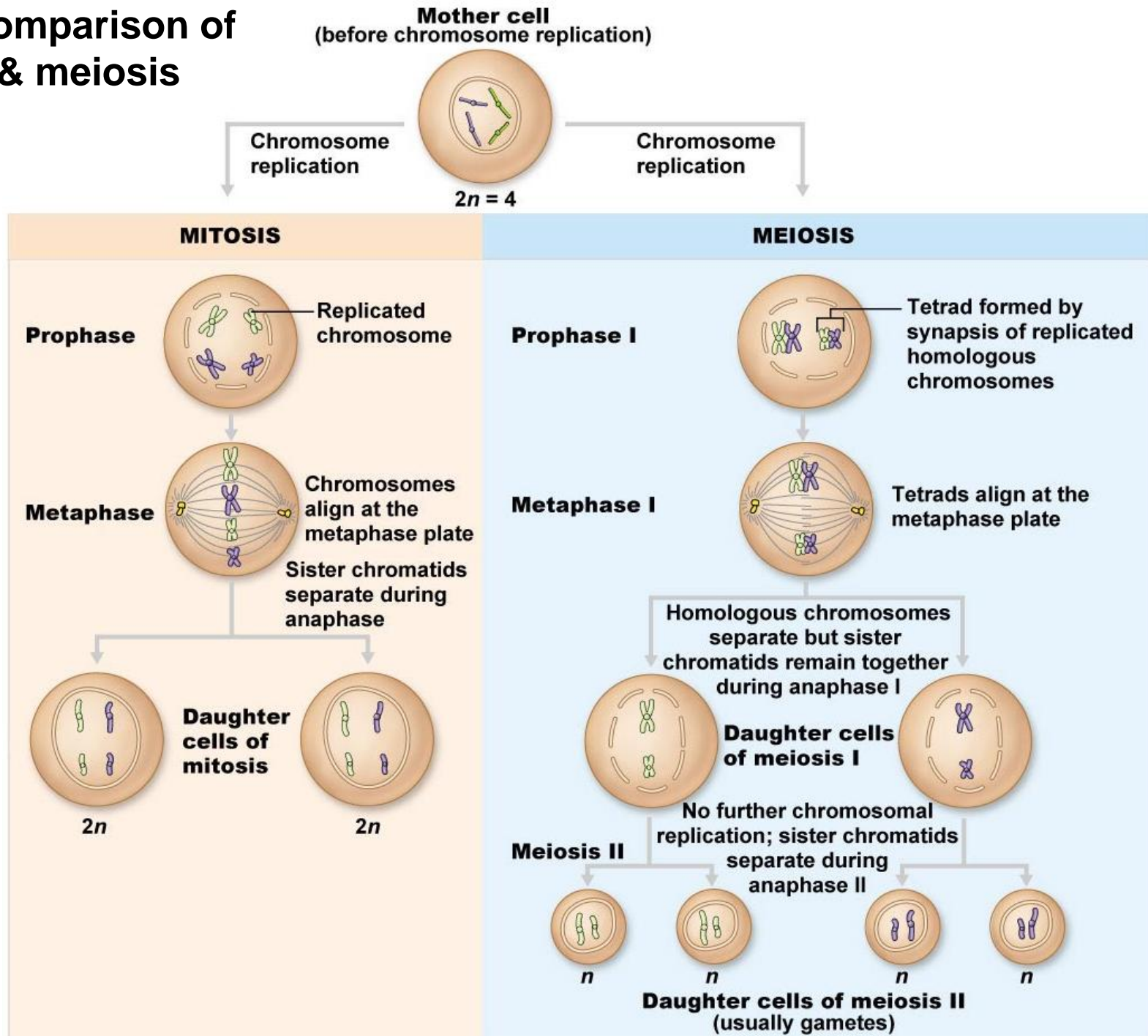
(iv) Spermatid:

- 22 autosomal chromatids + X or Y - still a **round** cell



From Fig. 27.8

Fig.27.5: Comparison of mitosis & meiosis



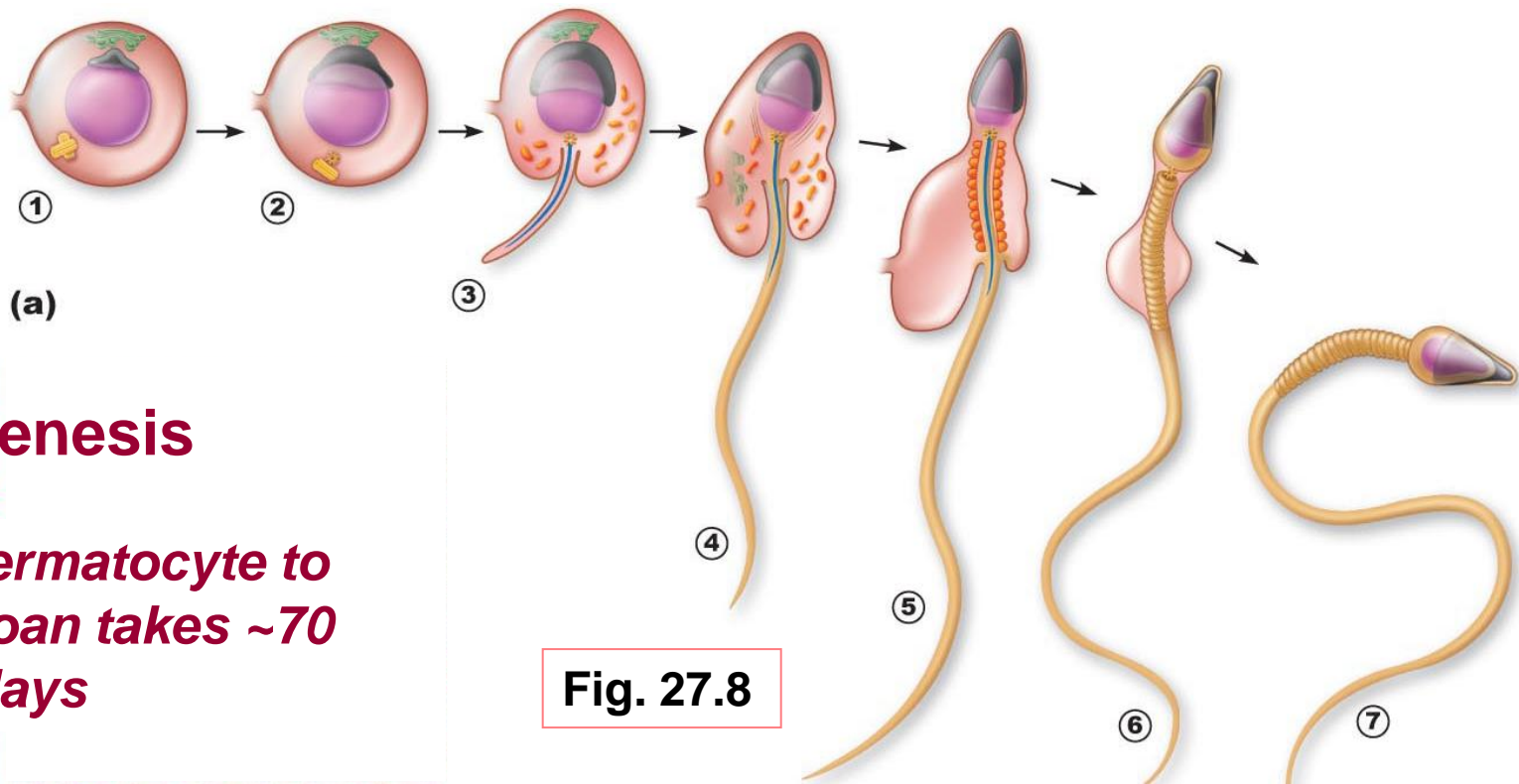


Fig. 27.8

Spermiogenesis

from 1^o spermatocyte to spermatozoan takes ~70 days

(v) Spermatozoan:

conversion of spermatid to spermatozoan requires structural reorganization

(i) reorganization of nucleus & cytoplasm

(ii) development of a flagellum

- spermatozoa then released into lumen; still not completely mature
- in epididymis will acquire ability: (i)
- (ii)

5.2.5 define blood-testis barrier & outline the functions of Sertoli & Leydig cells in supporting spermatogenesis

A. Role of Sertoli Cells

spermatids & spermatocytes at various stages embedded in Sertoli cells

Sertoli cells sit on basement membrane; tight junctions create 2 compartments:

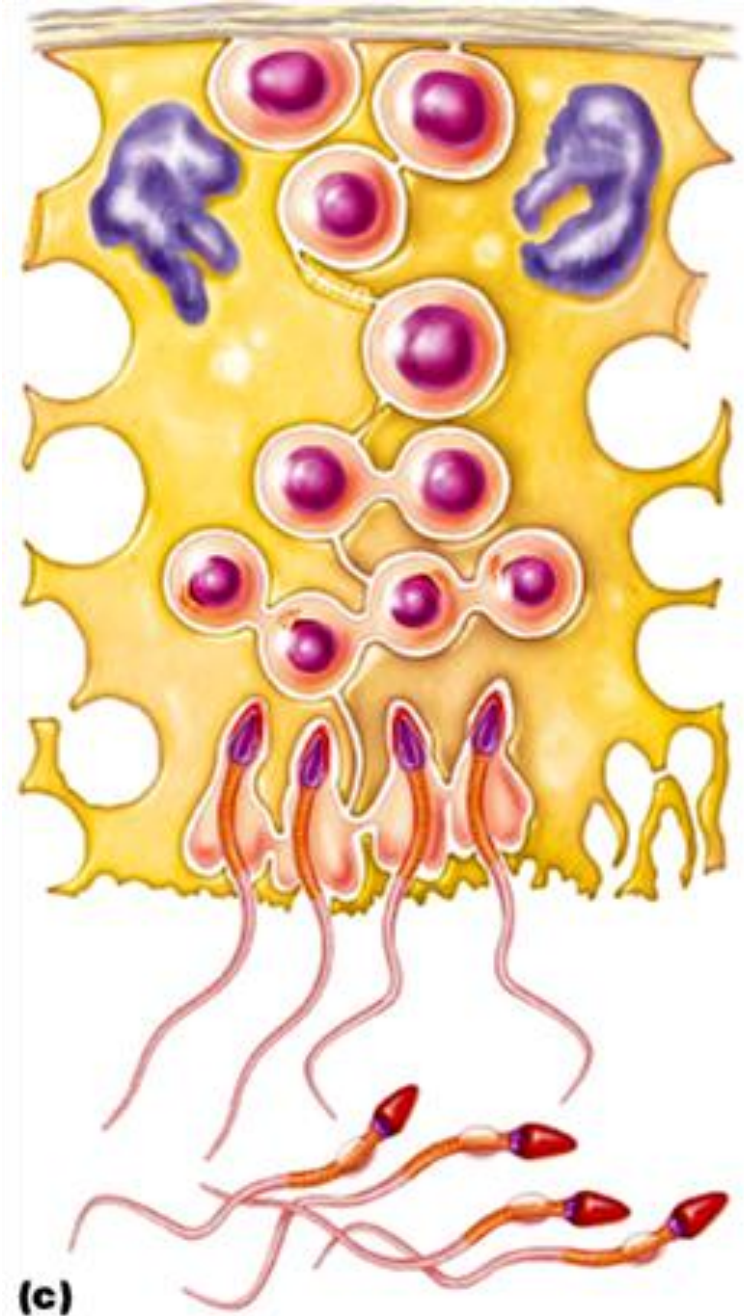
> **basal compartment:**

> **adluminal compartment:**

tight junctions create blood-testis barrier; all stages after initiation of meiosis occur in avascular environment

Sertoli cells:

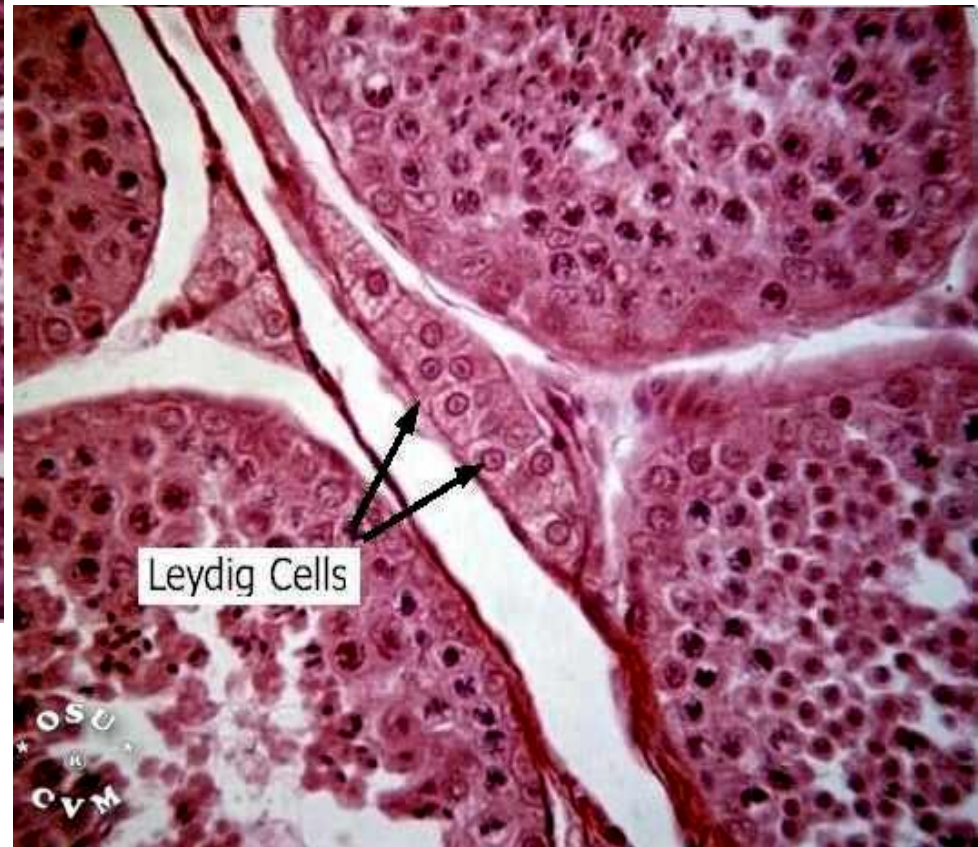
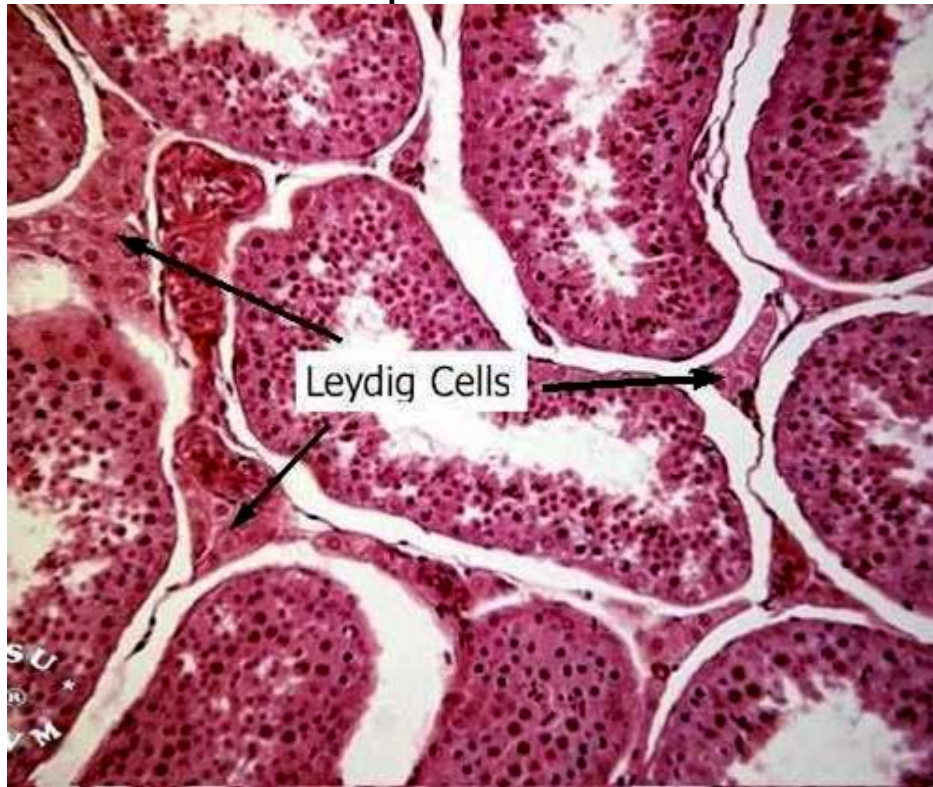
- (i) nourish developing spermatozoa
- (ii) secrete fluid into seminiferous tubule lumen
- (iii) digest cytoplasm discarded by spermatozoa
- (iv) bind FSH and testosterone
- (v) produce inhibin



From Fig. 27.8

B. Role of Leydig Cells

- located **between** seminiferous tubules
- **vascularized** - *why important?*
- receptors for **LH** - stimulated by LH to secrete testosterone to:
 - > support spermatogenesis



5.2.6 describe the functional contributions of the epididymis & the accessory organs to the production of semen

A. Epididymis

sperm spend ~20days here

further maturation – membrane & enzyme changes to permit:

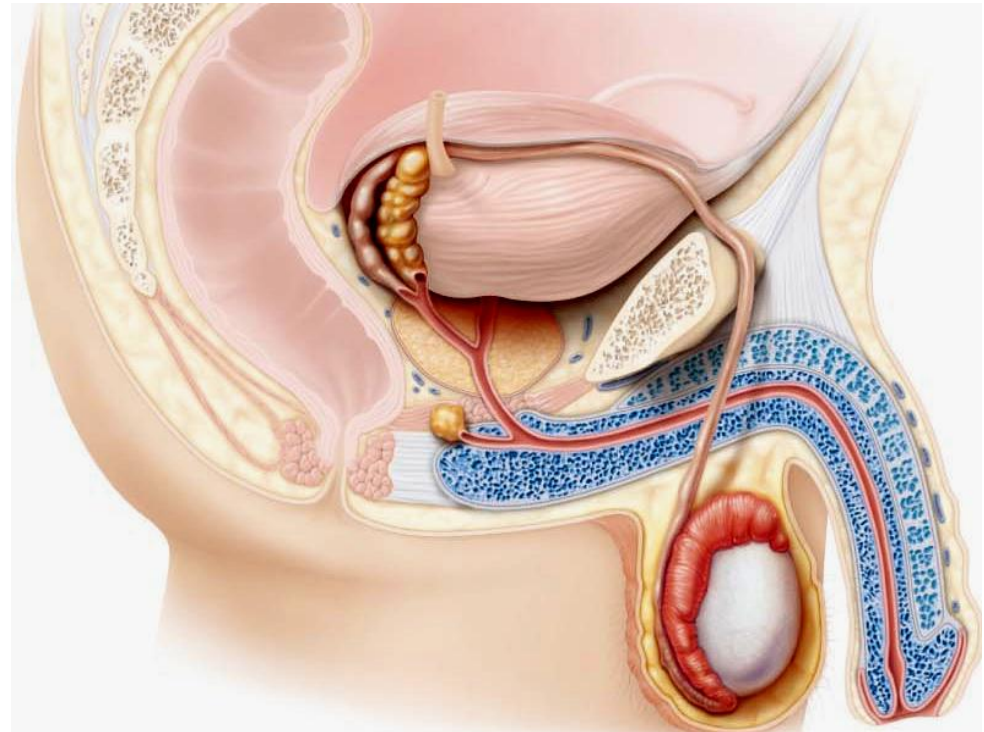
- > sustained motility
- > binding to egg

B. Seminal Vesicles

- secrete viscous, yellow fluid rich in **fructose**
- *Why fructose?*
- also contains **PGs** → *What do they do?*

C. Prostate Gland

- secrete thin, milky fluid to neutralize acidity of male urethra & female vagina



D. Bulbourethral Glands

thick, clear mucus

neutralizes traces of acidic urine in urethra

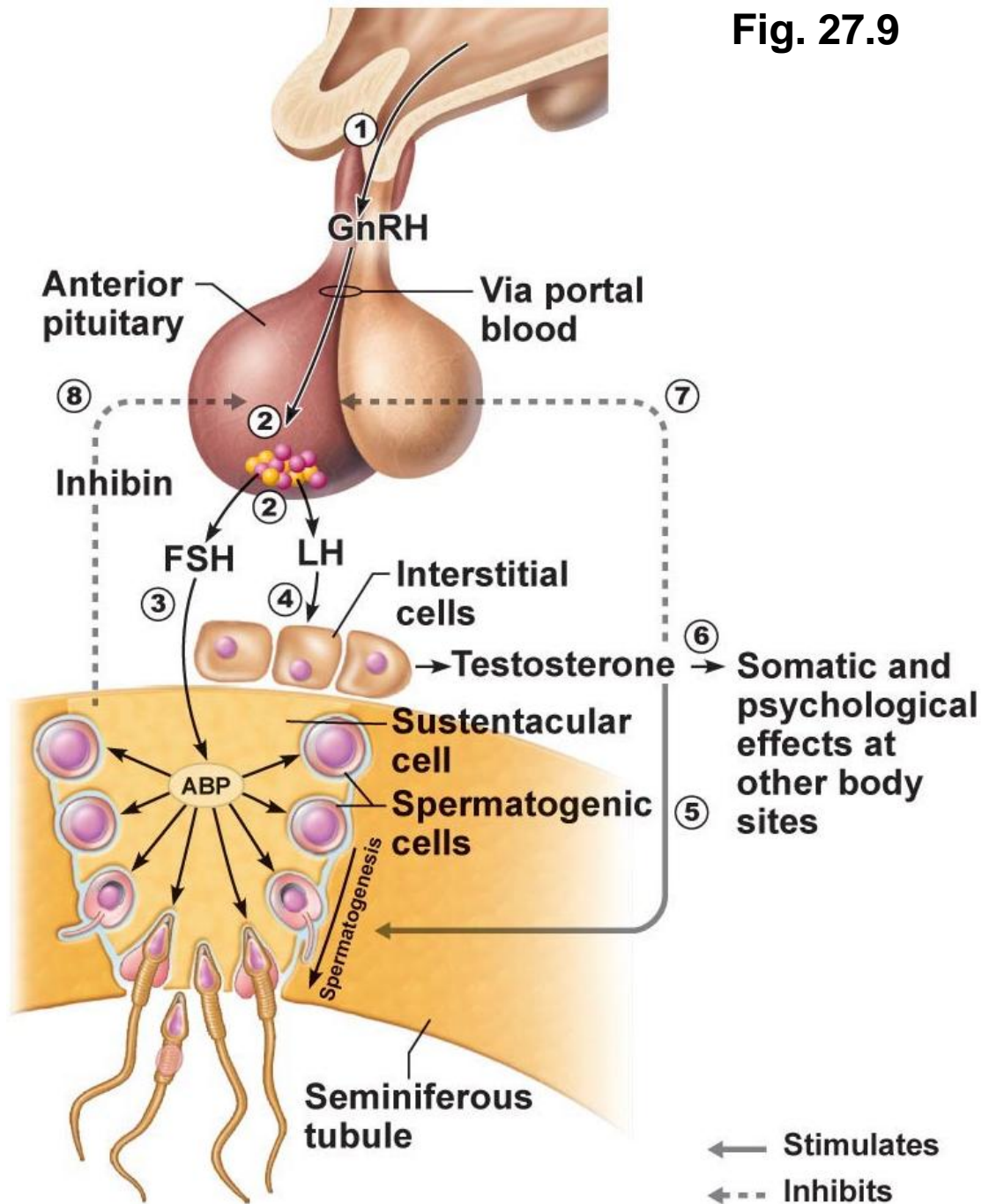
Fig. 27.9

Know sources & roles of :

- GnRH
- FSH
- LH
- testosterone
- inhibin

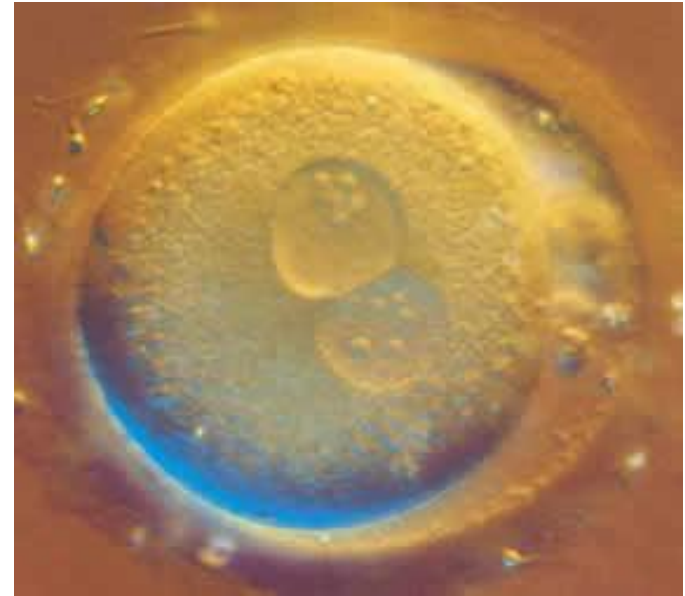Have an understanding of:

- hypothalamus
- anterior pituitary
- gonadotropin
- Sertoli cell
- Leydig cell



1. **A chromosome count in a spermatogenic cell within the adluminal compartment of the seminiferous tubule shows it to be diploid. The cell could be a:**

- a) spermatogonium
- b) spermatid
- c) Sertoli cell
- d) primary spermatocyte
- e) b and d



www.nvsh.nl/.../SS/Reproduction_Eicel.jpg

2. **Seminal vesicle secretions have:**

- a) a low pH
- b) fructose
- c) prostaglandins
- d) sperm-activating enzymes
- e) b and c

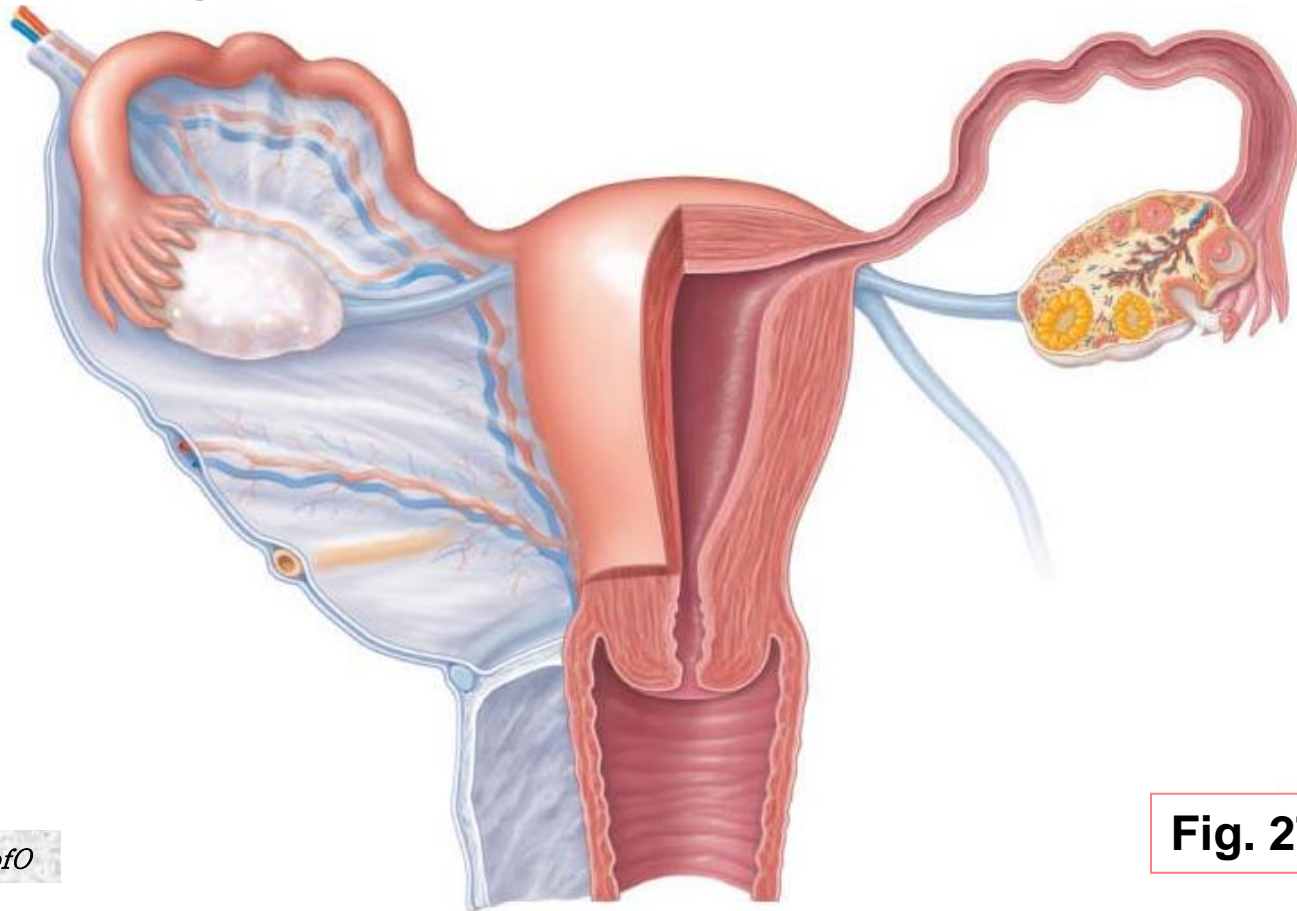
3. **Which of the following statements about gonadotropins is FALSE?**

- a) secreted by the pituitary gland
- b) LH and FSH
- c) hormones with important functions in both ♂ and ♀
- d) the sex hormones secreted by the gonads

5.3 Describe the anatomy of the female reproductive system

5.3.1 describe the gross and microscopic anatomy of the ovaries

- female reproductive system more complex ➤ must:
 - (i) produce gametes
 - (ii) prepare to nurture developing embryo
 - **internal genitalia:** ovaries
 - **accessory ducts:** uterine tubes (oviducts), uterus, vagina
 - **external genitalia:** vulva



Ovaries

- anchored by ligaments
**ovarian
suspensory
mesovarium**

*NB: suspensory/mesovarium ligaments are part of **broad ligament** that supports uterine tubes, uterus, vagina*

- ovarian arteries (branches of ???) & ovarian branch of uterine arteries

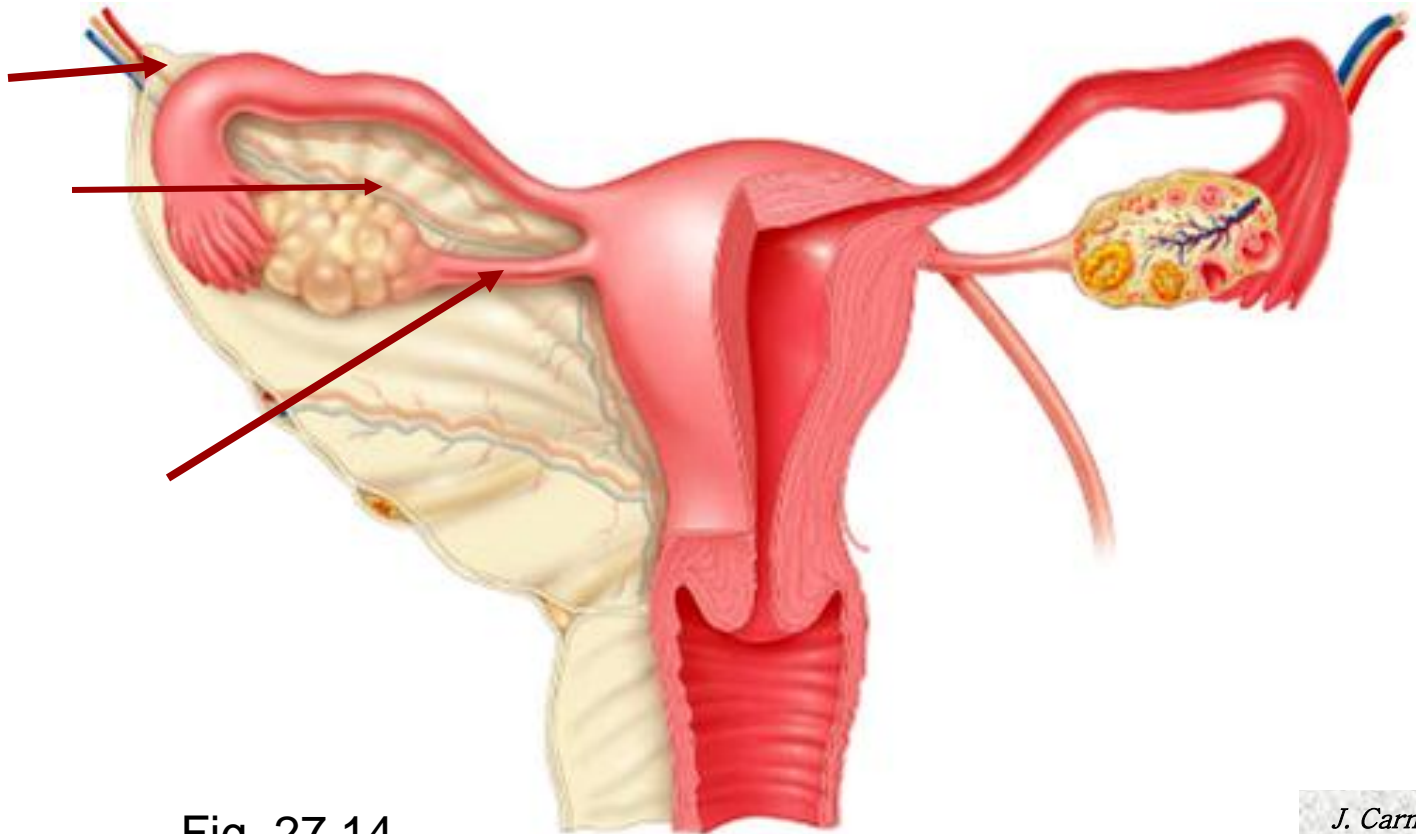
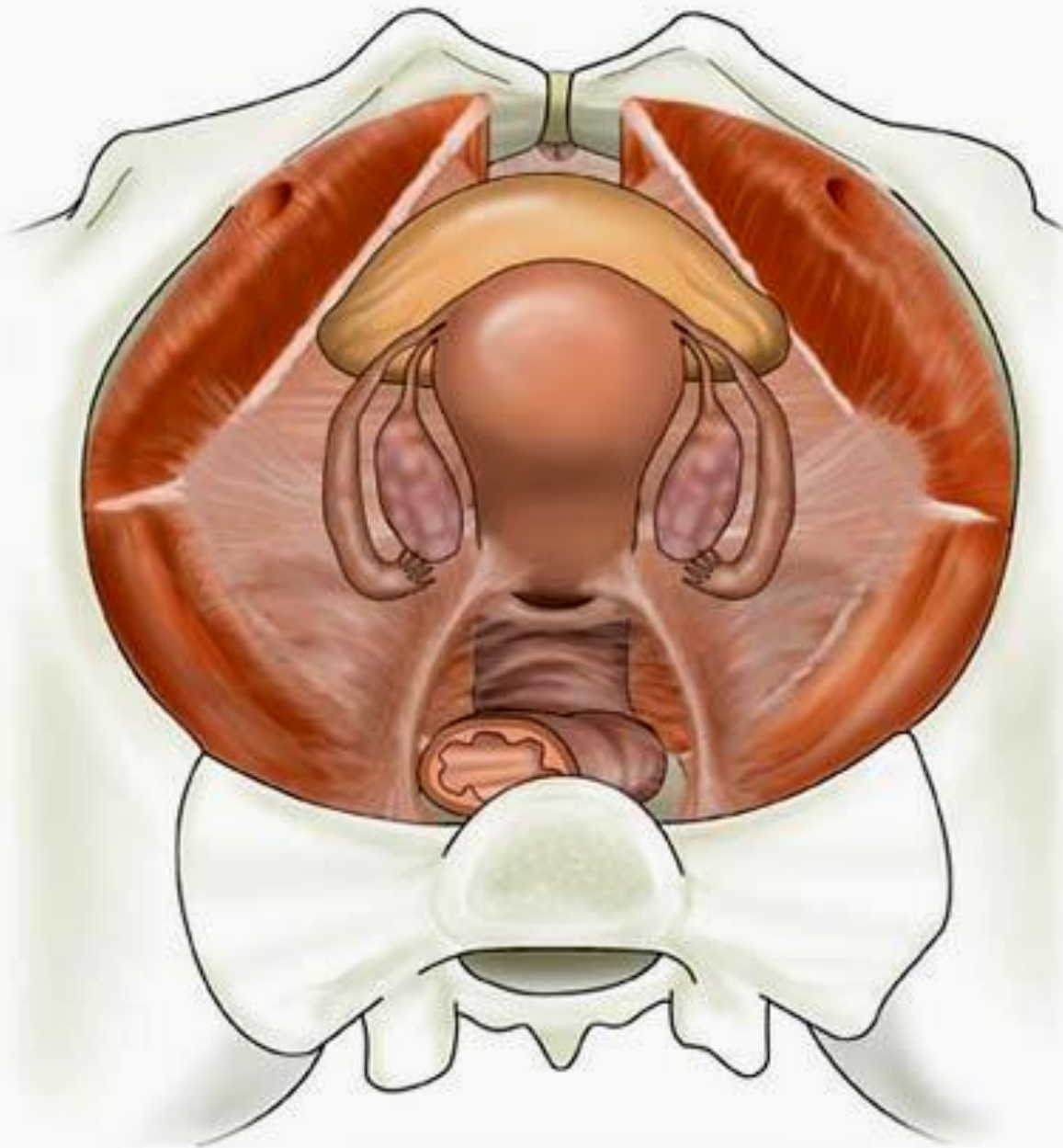


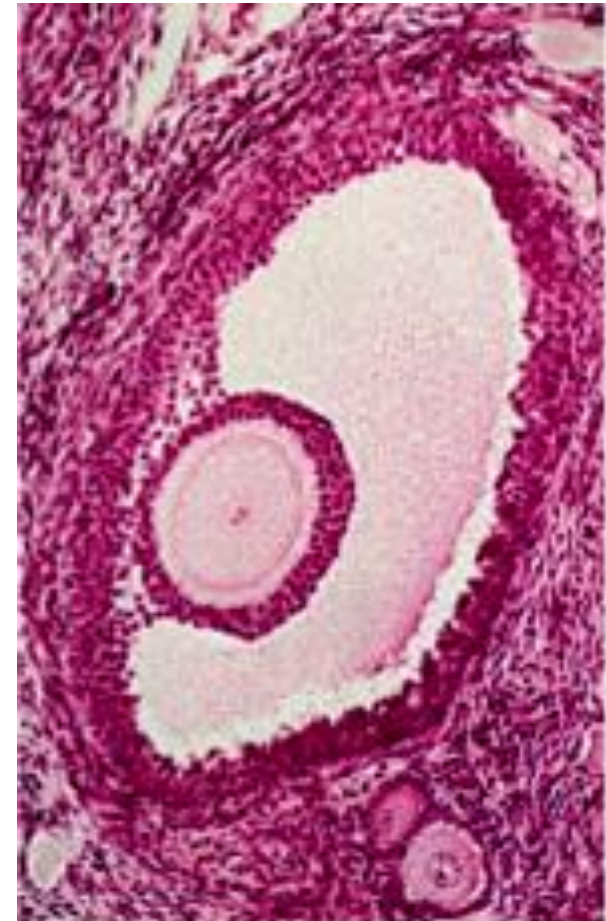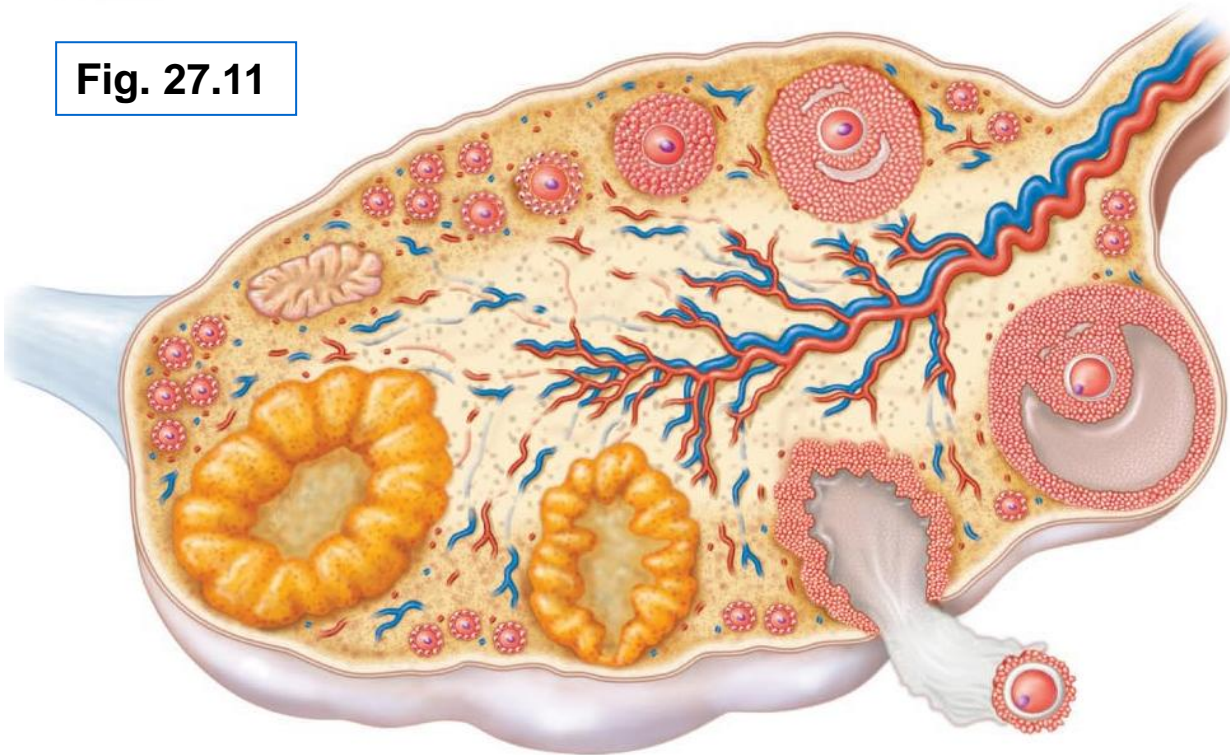
Fig. 27.14



<http://www1.tpg.com.au/users/sfrancis/med/uterus.jpg>

ext surface covered by **tunica albuginea**
final outer covering is **germinal epithelium**
ovarian **cortex** contains **follicles** at all stages of development
oocyte
granulosa cells
theca cells
corpus luteum formed from ovulated follicle each month

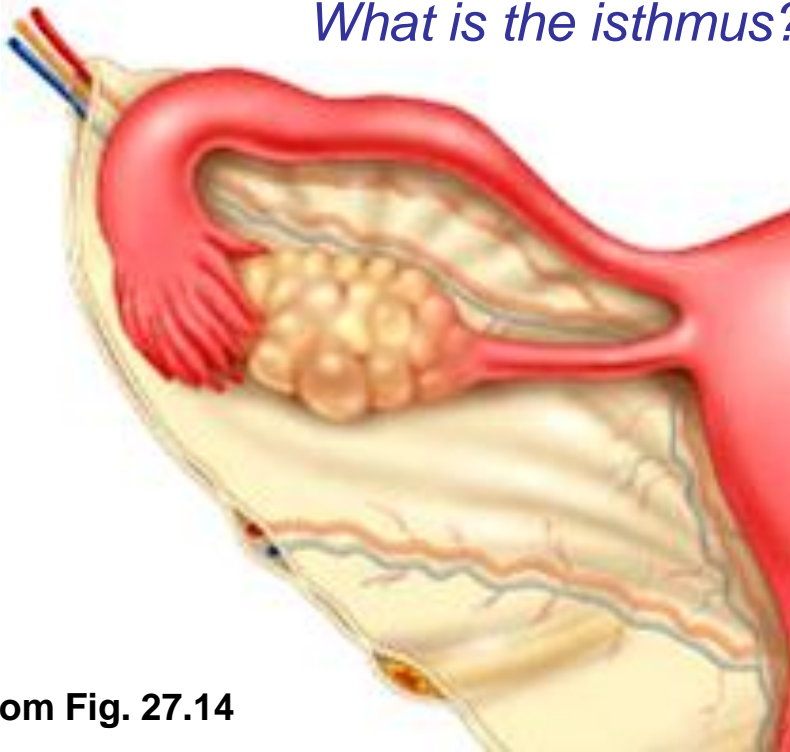
Fig. 27.11



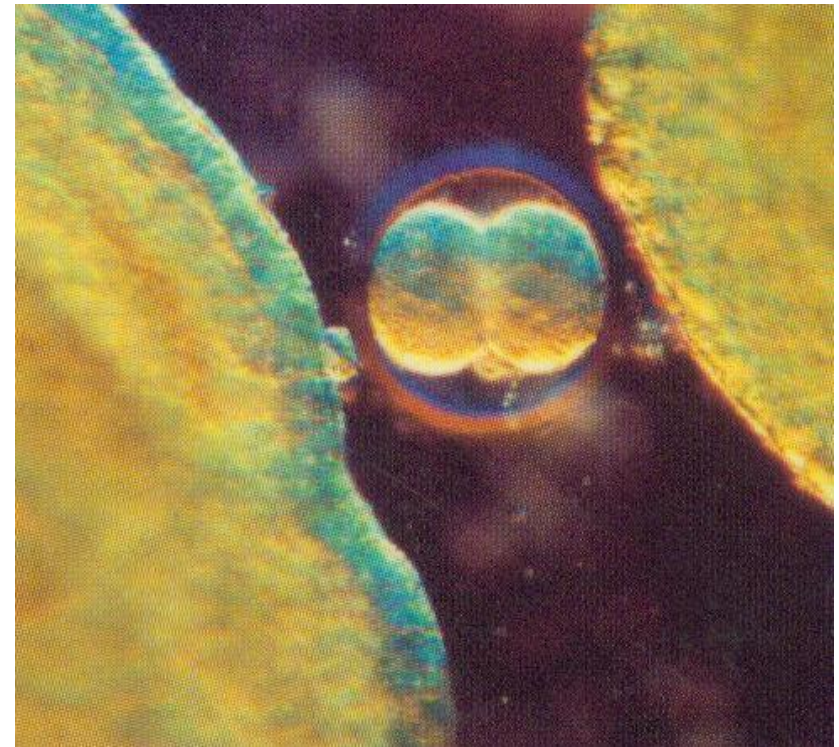
5.3.2 describe the gross and microscopic anatomy of the oviducts

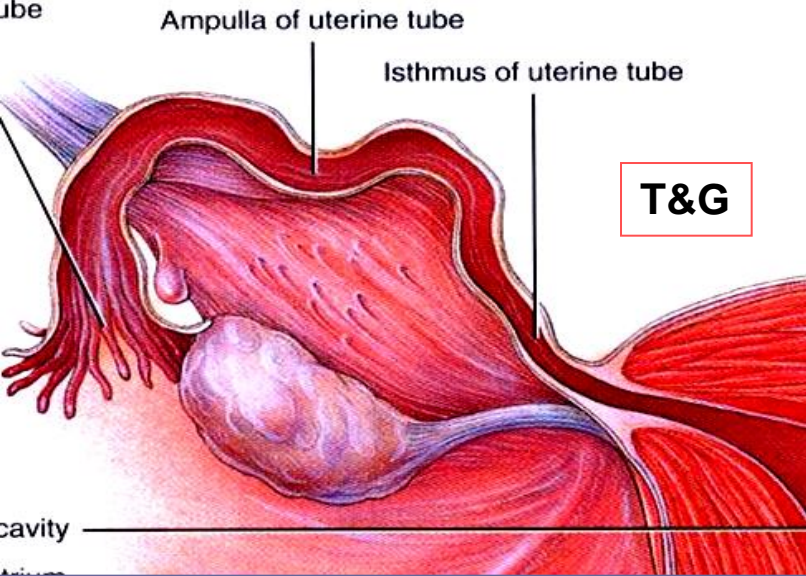
- receive egg & provide site for fertilization; ~ 10 cm long
- **ampulla**, **infundibulum**, **fimbriae**: oocyte released into peritoneal cavity ➤ fimbriae direct it into ampulla of oviduct
- structure of wall of oviduct also helps oocyte move toward uterus:
 - 1)
 - 2)
- ext covering = visceral peritoneum; supported by **mesosalpinx**

What is the isthmus?



From Fig. 27.14





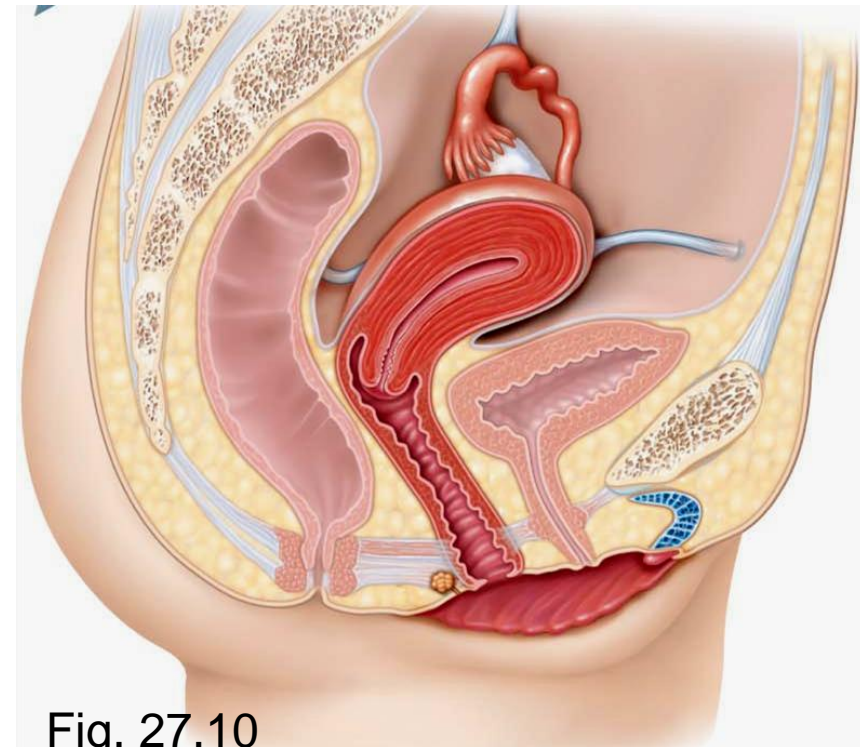
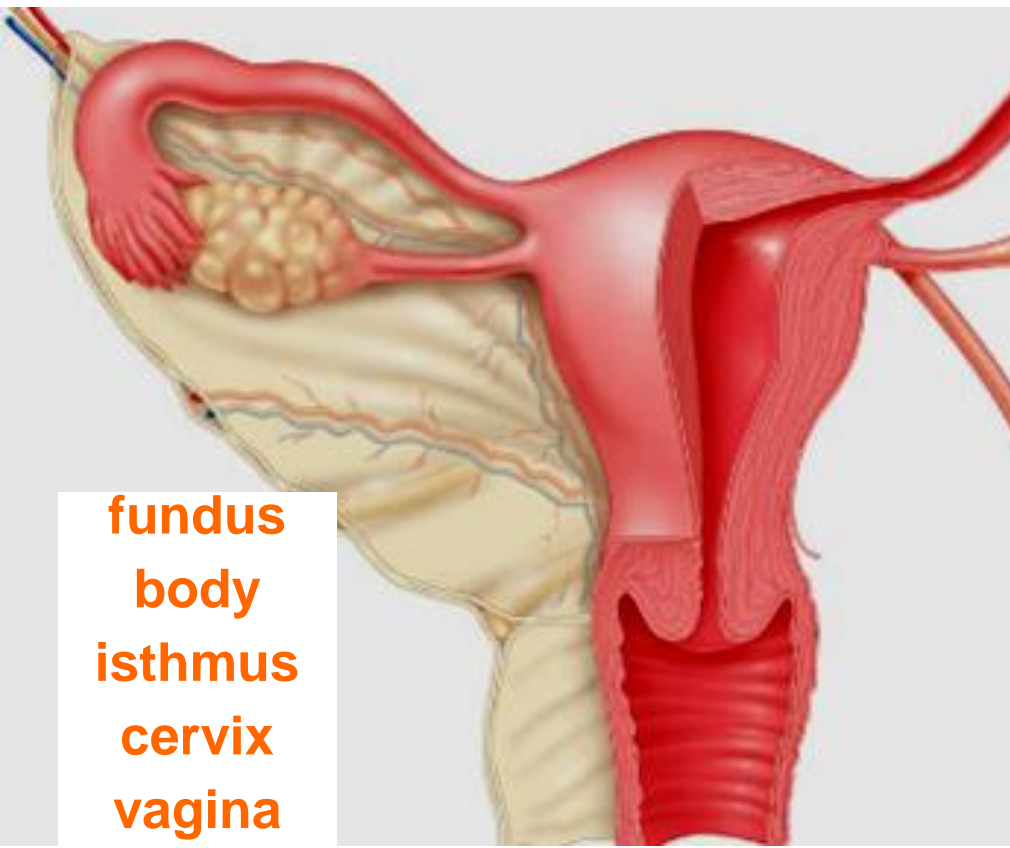
5.3.3 describe the gross & microscopic anatomy of the uterus

- anterior to rectum & postero-superior to bladder
- receives, retains, nourishes embryo
- inverted pear in **nulliparous women**

internal os: uterus to cervix

external os: cervix to vagina

cervical glands: mucus fills cervical canal & covers ext os ➤ prevents infection; less viscous at midcycle – **why??**



Supports of Uterus:

mesometrium: laterally (broad ligament)

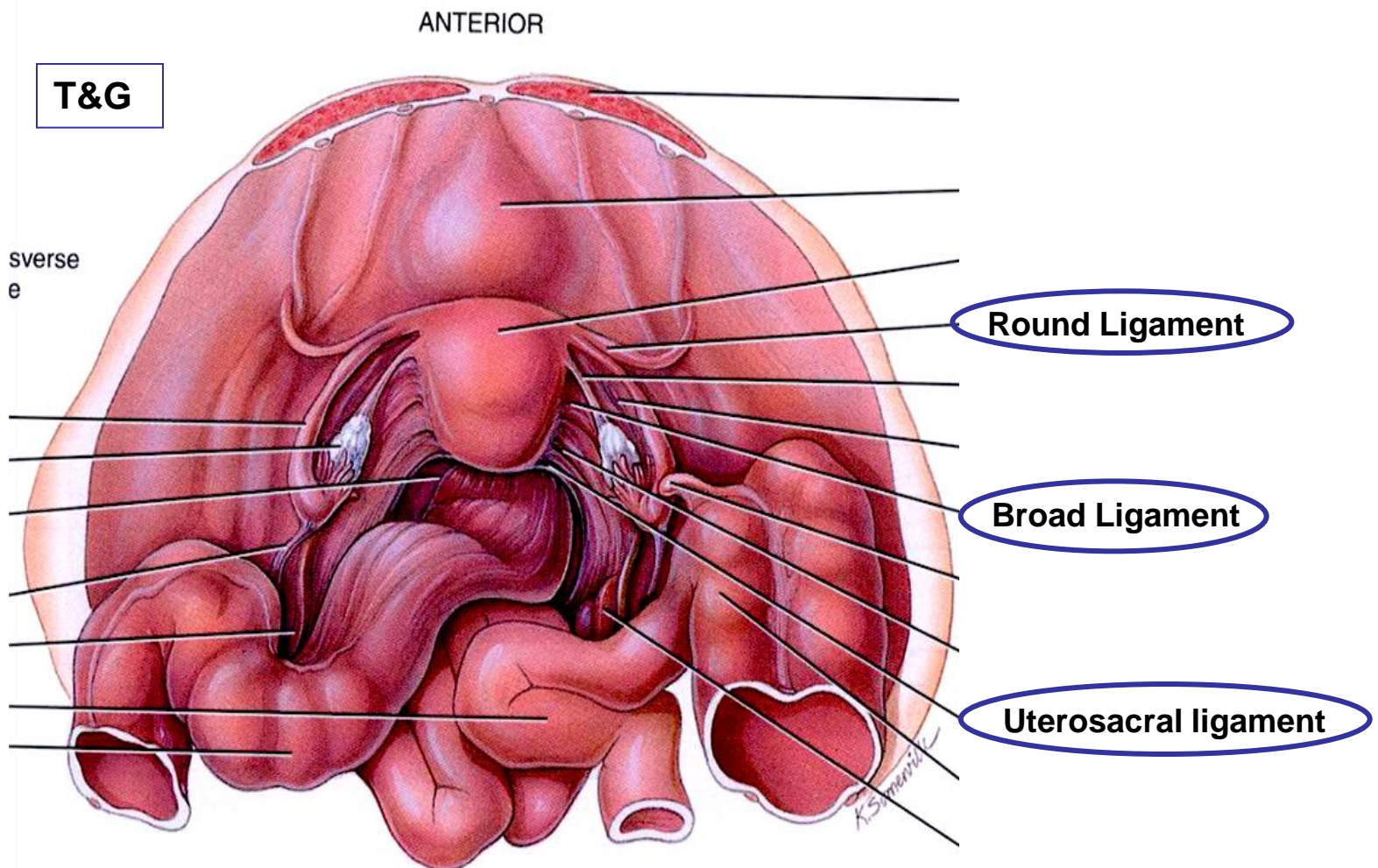
lateral cervical ligaments: inferiorly; from cervix & upper vagina to lat walls of pelvis

uterosacral ligaments: to sacrum posteriorly

round ligaments: to anterior body wall

- supports allow mobility (eg: during ???)
- principal support by muscles of pelvic floor (urogenital & pelvic diaphragms)

*J. Carnegie,
UofO*



Uterine Wall:

- 3 layers:

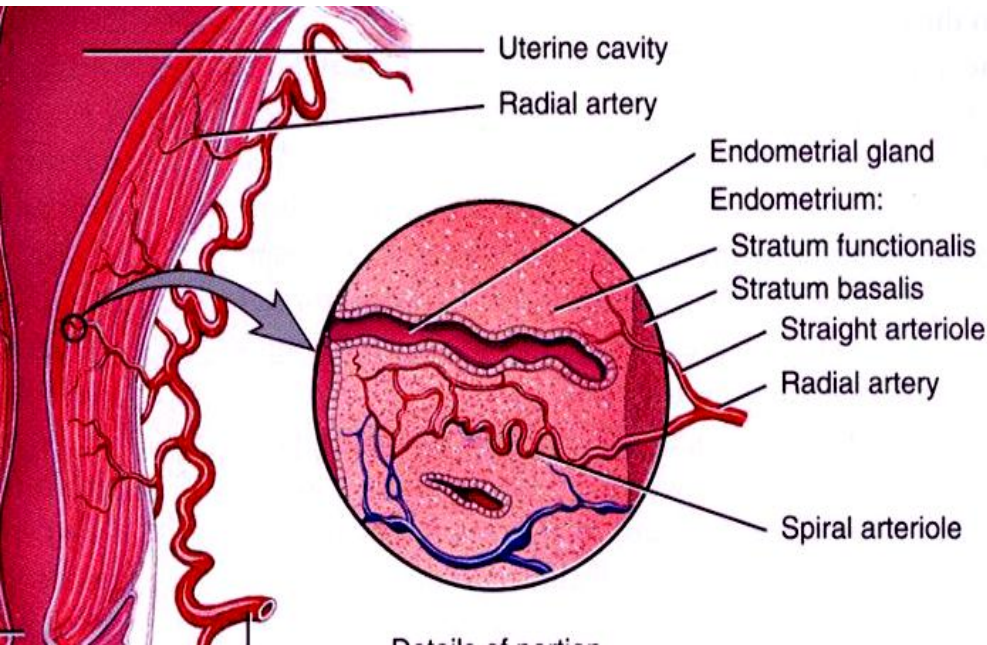
perimetrium: = visceral peritoneum

myometrium: middle, interlacing bundles of smooth muscle

endometrium: simple columnar epithelium + thick lamina propria

stratum functionalis:

stratum basalis:



Stratum functionalis of the endometrium

Stratum basalis of the endometrium

Portion of the myometrium

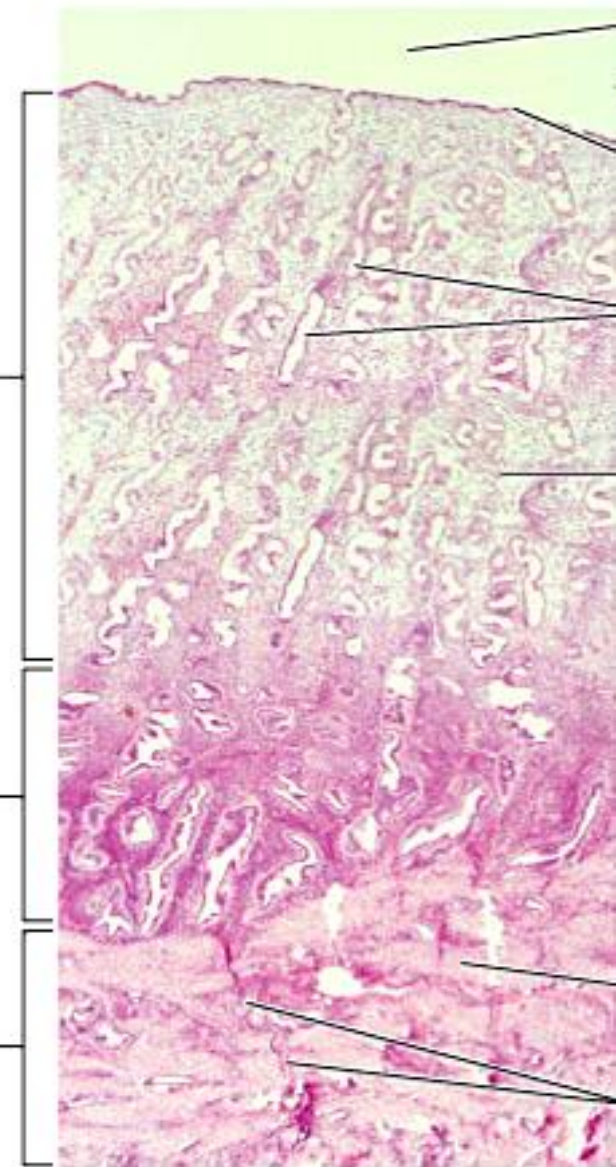


Fig. 27.15a

T&G

J. Carnegie, UofO

vascular supply:

uterine arteries (from internal iliacs)

branches into uterine wall

arcuate arteries within myometrium

straight arteries
(stratum basalis)

spiral arteries
(stratum functionalis)

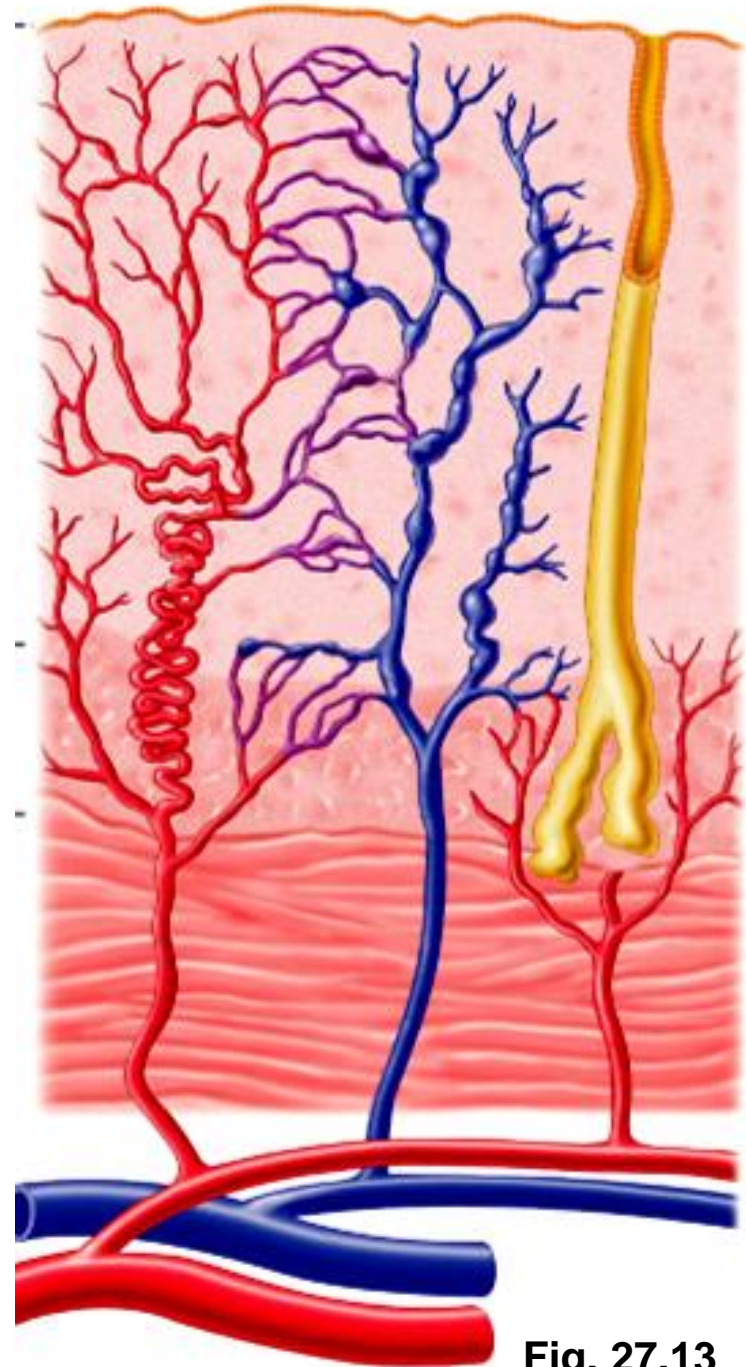


Fig. 27.13

5.3.4 describe the anatomy of the vagina & the external genitalia

thin-walled tube, 8-10 cm long

urethra embedded in anterior wall

passageway for:

entry of sperm

exit of menstrual flow

delivery of infant

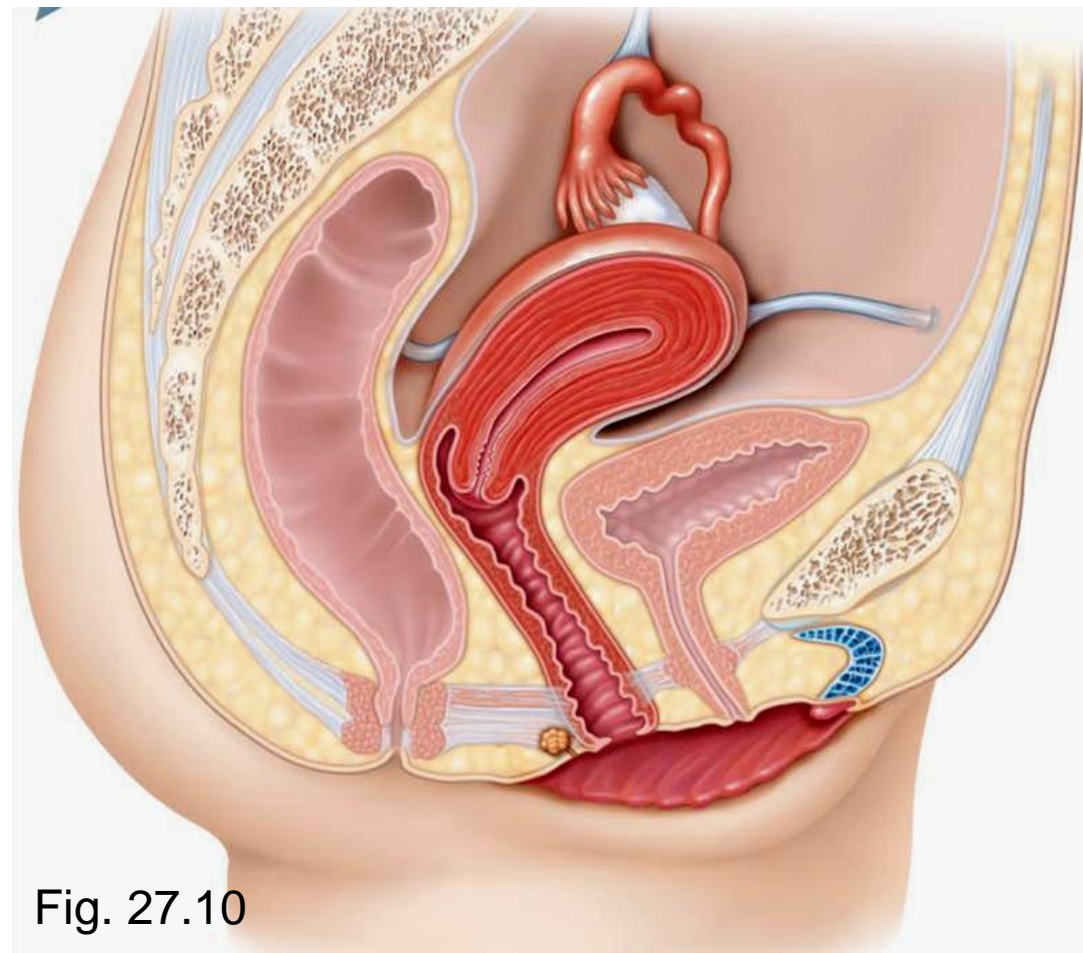


Fig. 27.10

J. Carnegie, UofO

- 3 layers:

adventitia: outer, fibroelastic

muscularis: smooth muscle

mucosa: inner, transverse **rugae**; stratified squamous epithelium (**why??**)

- no glands; lubrication provided by cervical glands

- epithelial cells store glycogen ➤ metabolized to lactic acid by resident bacteria ➤ acidic pH deters infection, but is hostile to sperm

hymen: incomplete vascular partition of mucosa near vaginal orifice in virgins

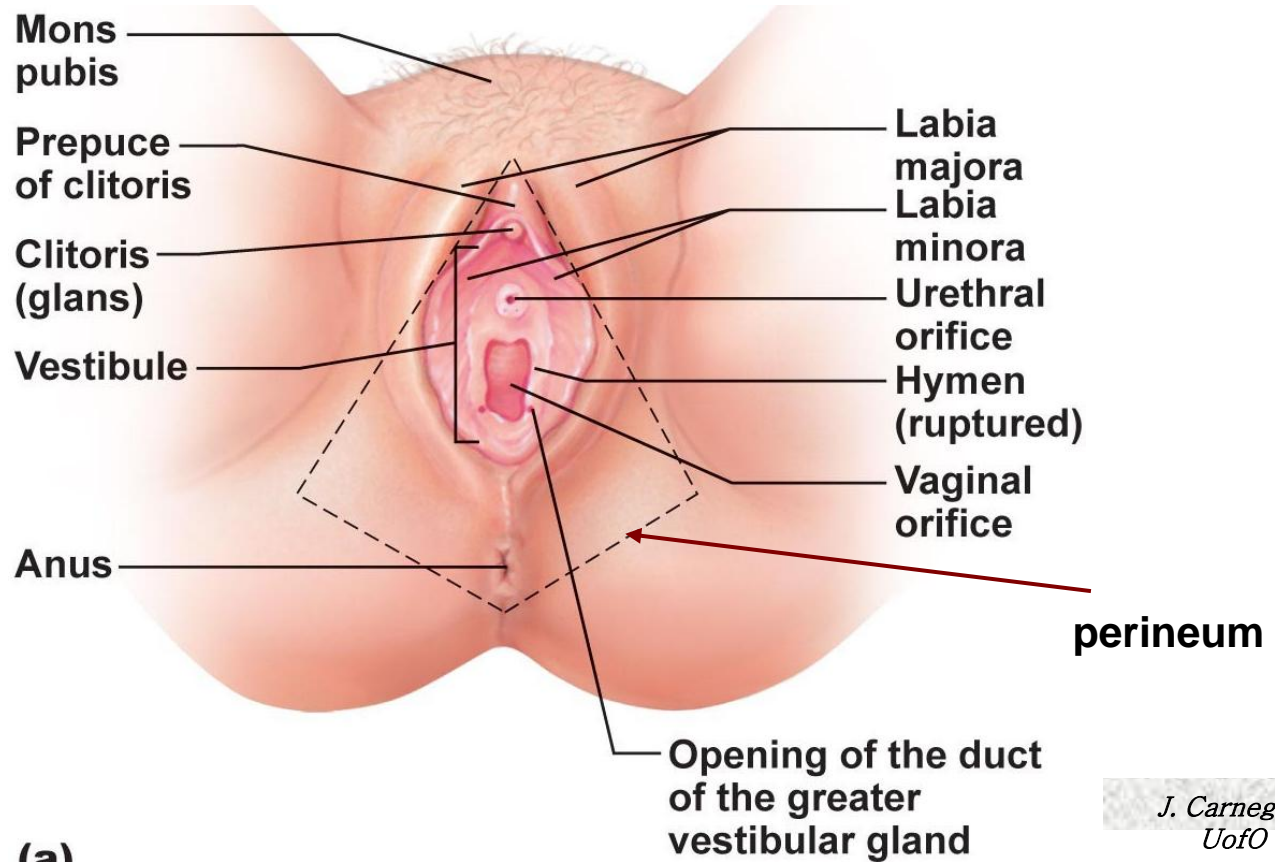


Fig. 27.16

*J. Carnegie,
UofO*

External Genitalia

- **vulva:** mons pubis, labia, clitoris, structures associated with vestibule
- mons pubis:** fatty, rounded area overlying pubic symphysis; covered with hair
- labia majora:** elongated, hair-covered fatty skin folds (homologue of scrotum)
- labia minora:** thin, hair-free skin folds enclosed by labia majora
- vestibule:** recess between labia minora - contains external opening of urethra & vaginal opening; greater vestibular glands
- clitoris:** erectile tissue (homologous to penis); hooded by skin fold; richly innervated; corpora cavernosa but no corpus spongiosum



1. Identify the following female anatomical structures:

- _____ 1. Chamber that houses the developing fetus.
- _____ 2. Canal that receives the penis during sexual intercourse.
- _____ 3. Usual site of fertilization.
- _____ 4. Becomes erect during sexual stimulation.
- _____ 5. Duct through which the ovum travels to reach the uterus.
- _____ 6. Membrane that partially closes vaginal canal.
- _____ 7. Primary female reproductive organ.
- _____ 8. Move to create fluid currents to draw the ovulated egg into the uterine tube.

2. What are some consequences of the fact that the uterine tubes are not structurally continuous with the ovaries? Address this question from both reproductive and health aspects.

