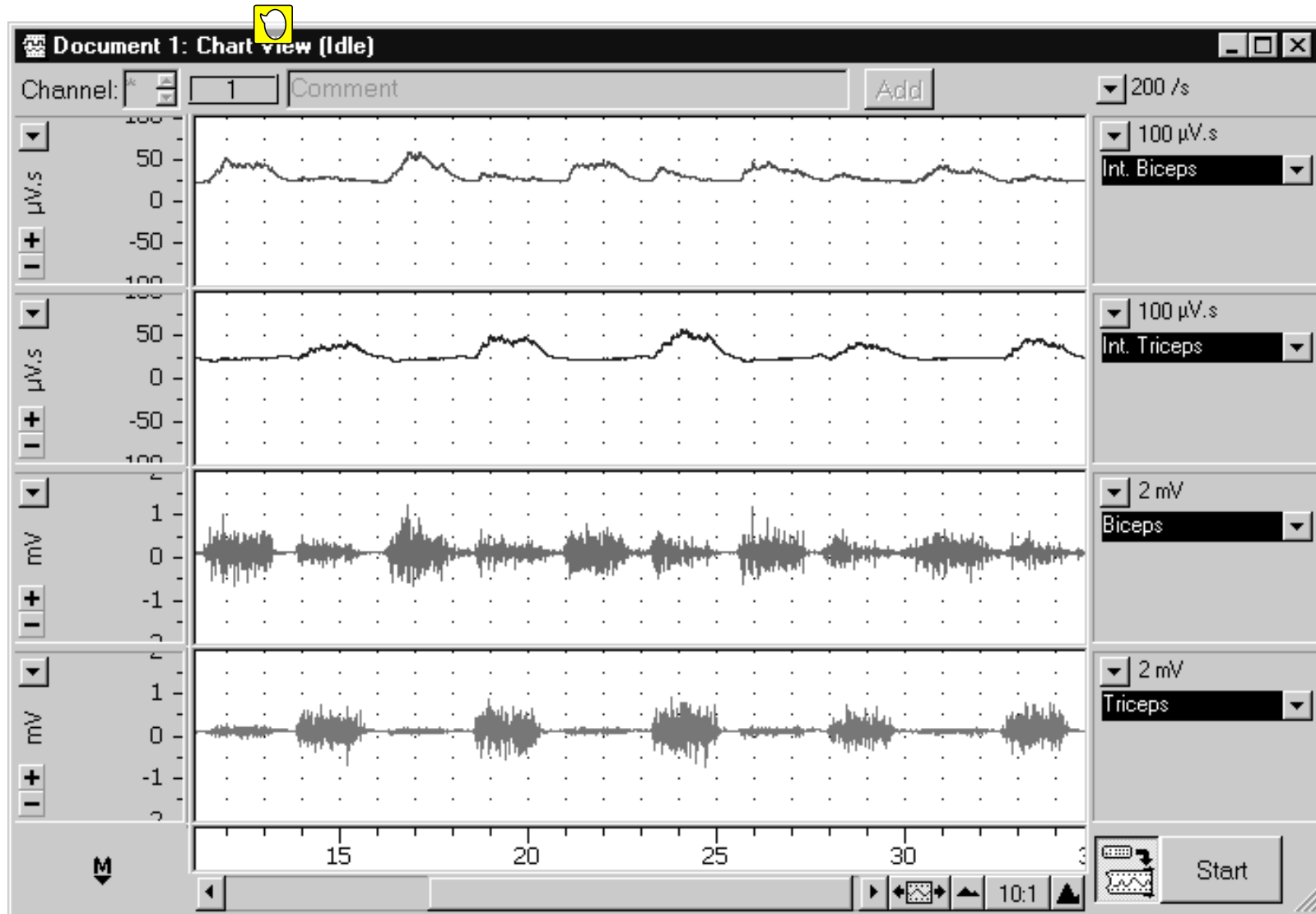


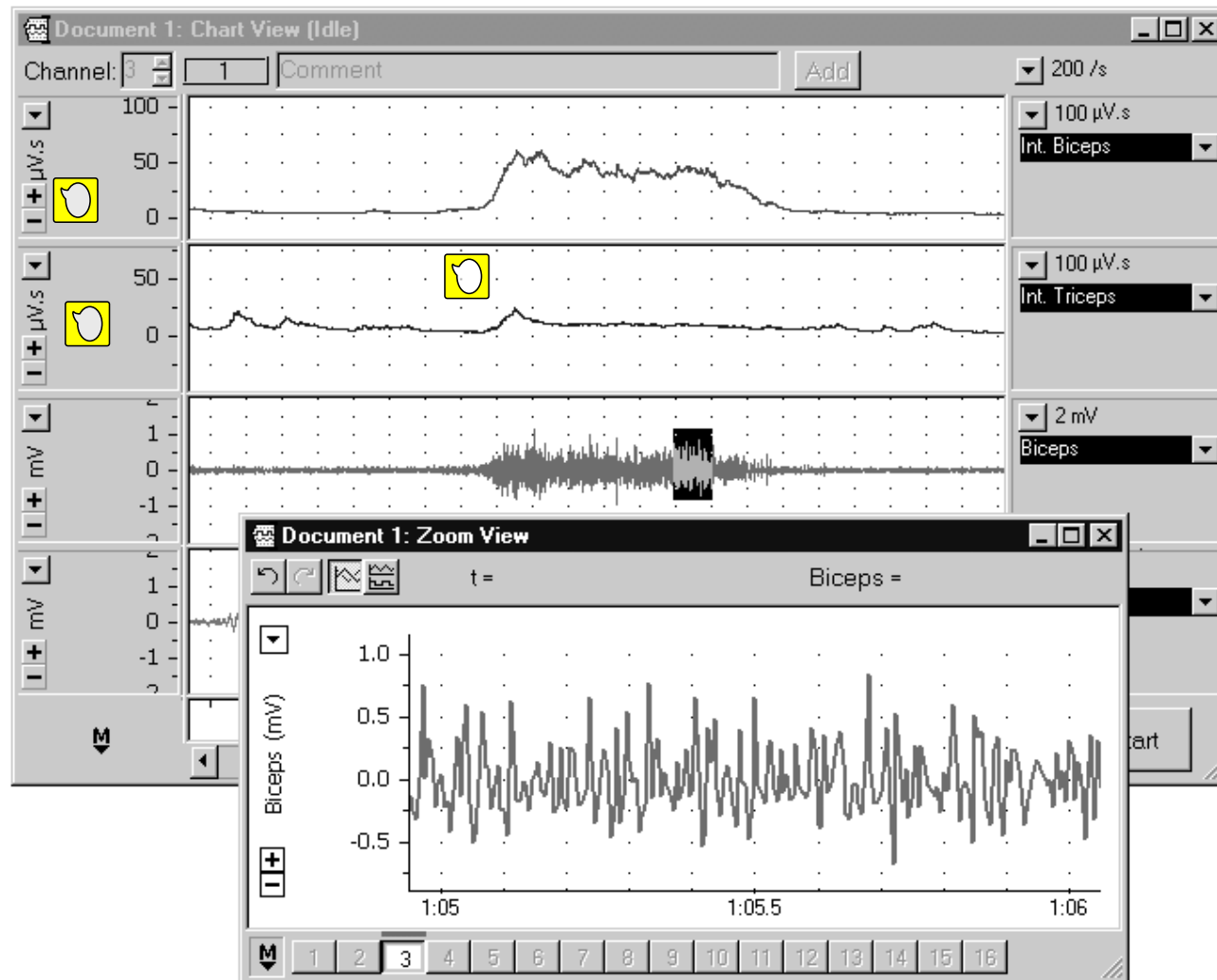
Lab 5 IMAGES

Muscle Anatomy and Physiology



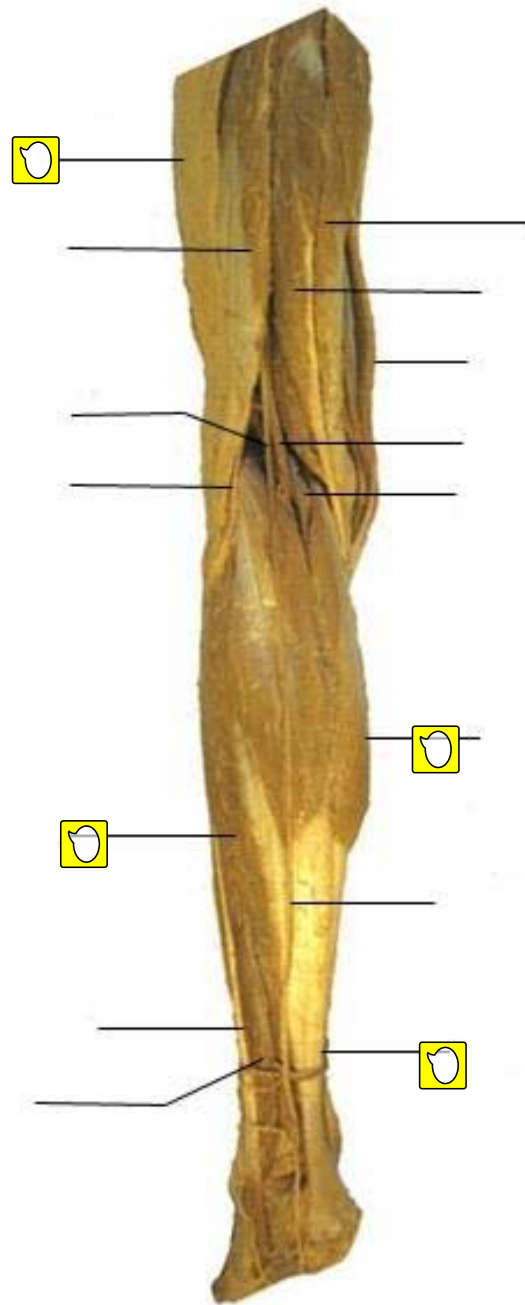
Alternating EMG activity in biceps and triceps muscles.





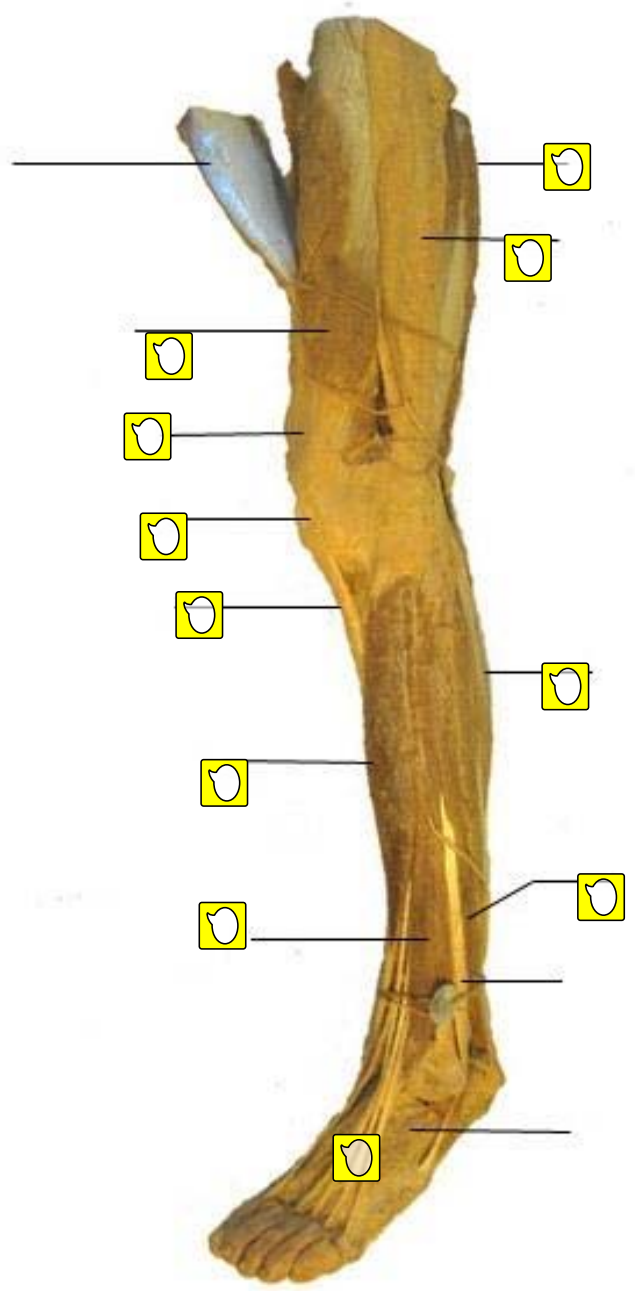
Burst of EMG activity in biceps muscle while supporting a weight

Thigh and Leg Posterior View



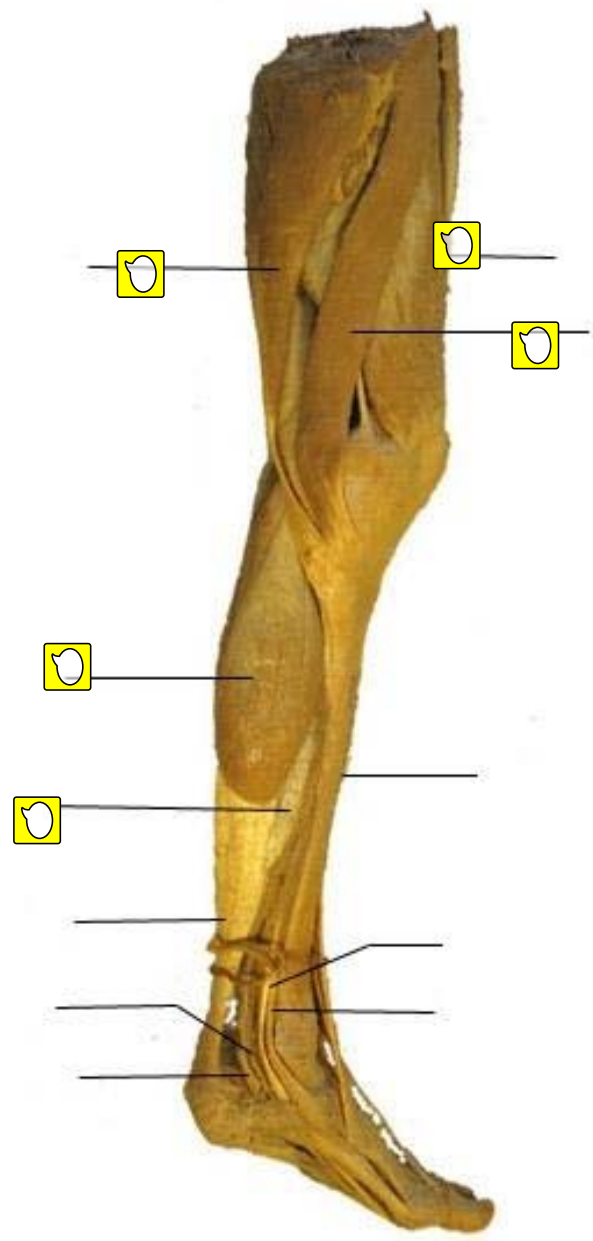
Thigh and Leg

Lateral View



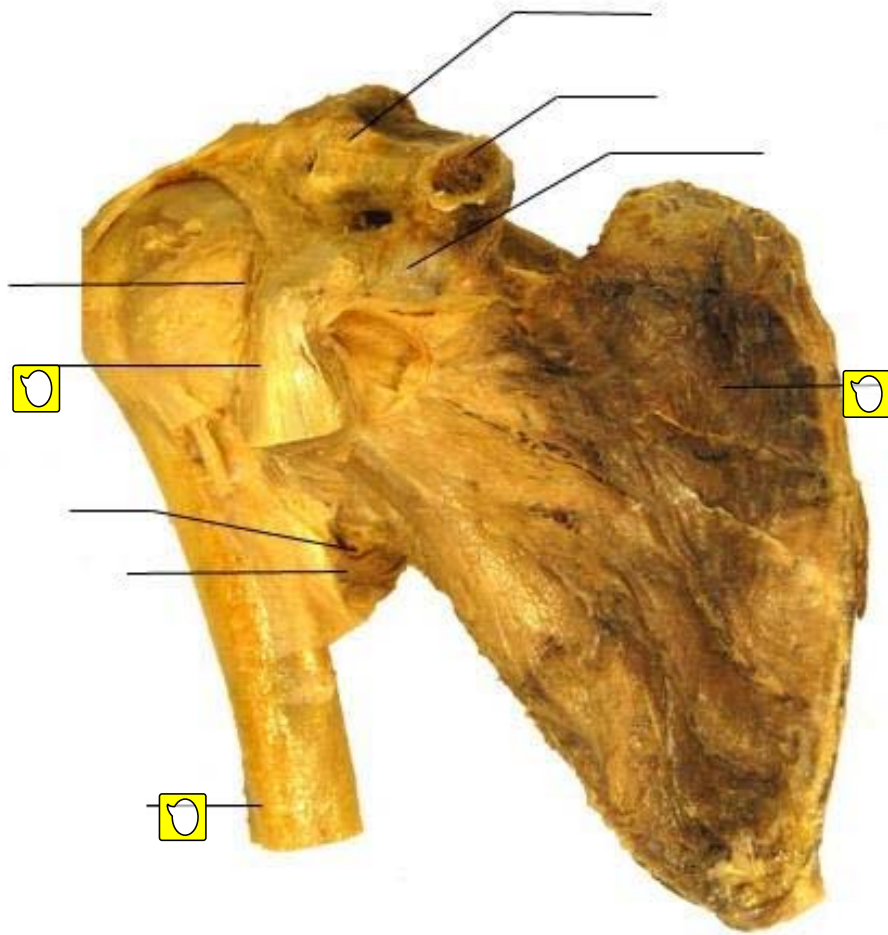
Thigh and Leg

Medial View



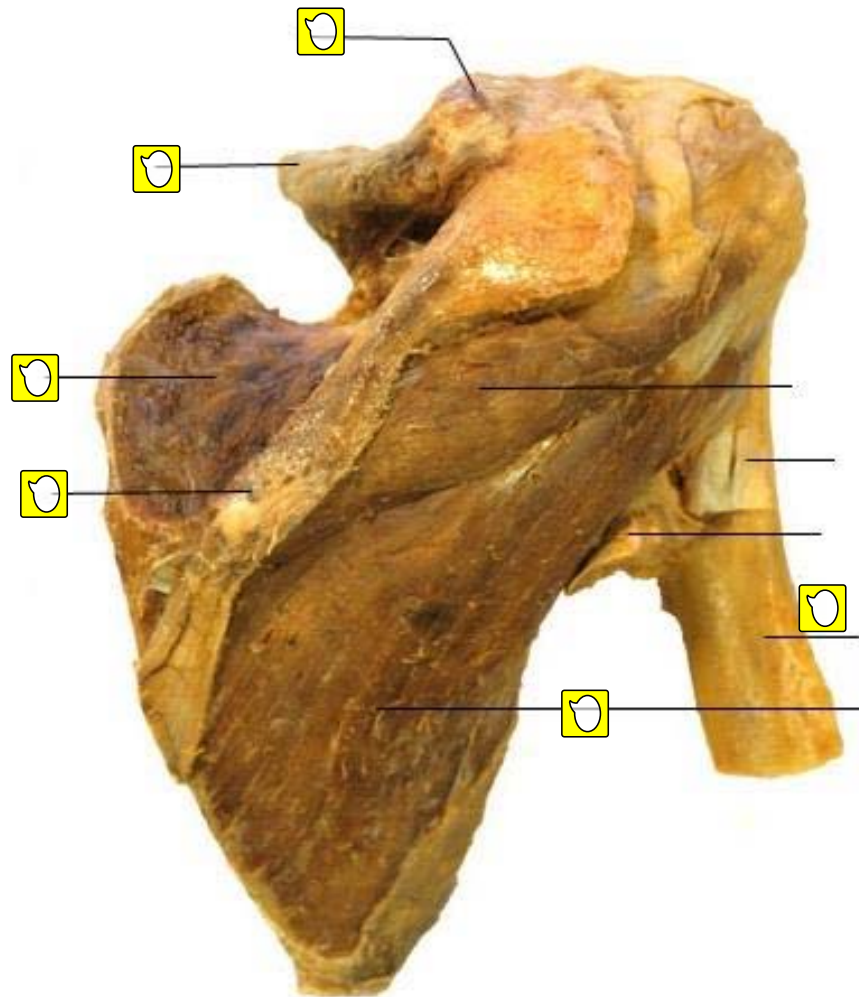
Scapula

Anterior View



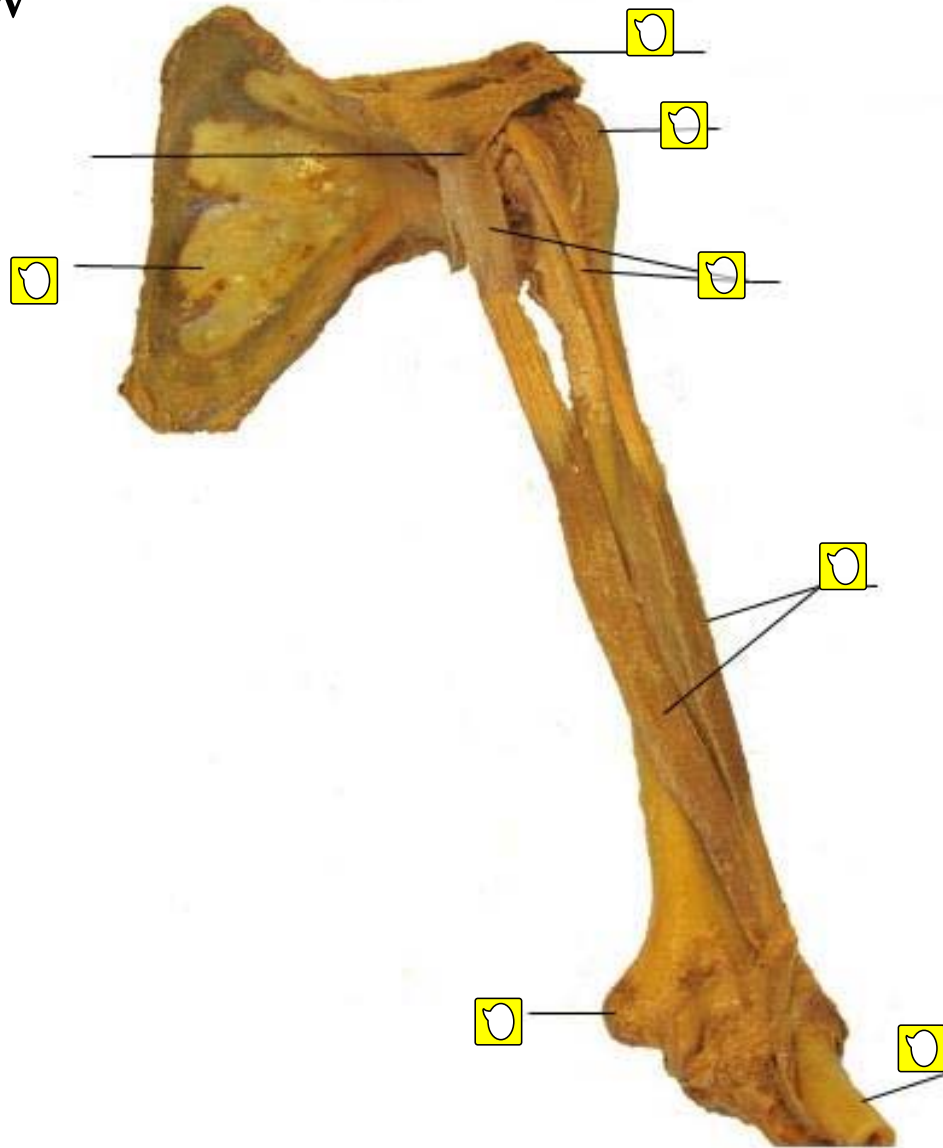
Scapula

Posterior View



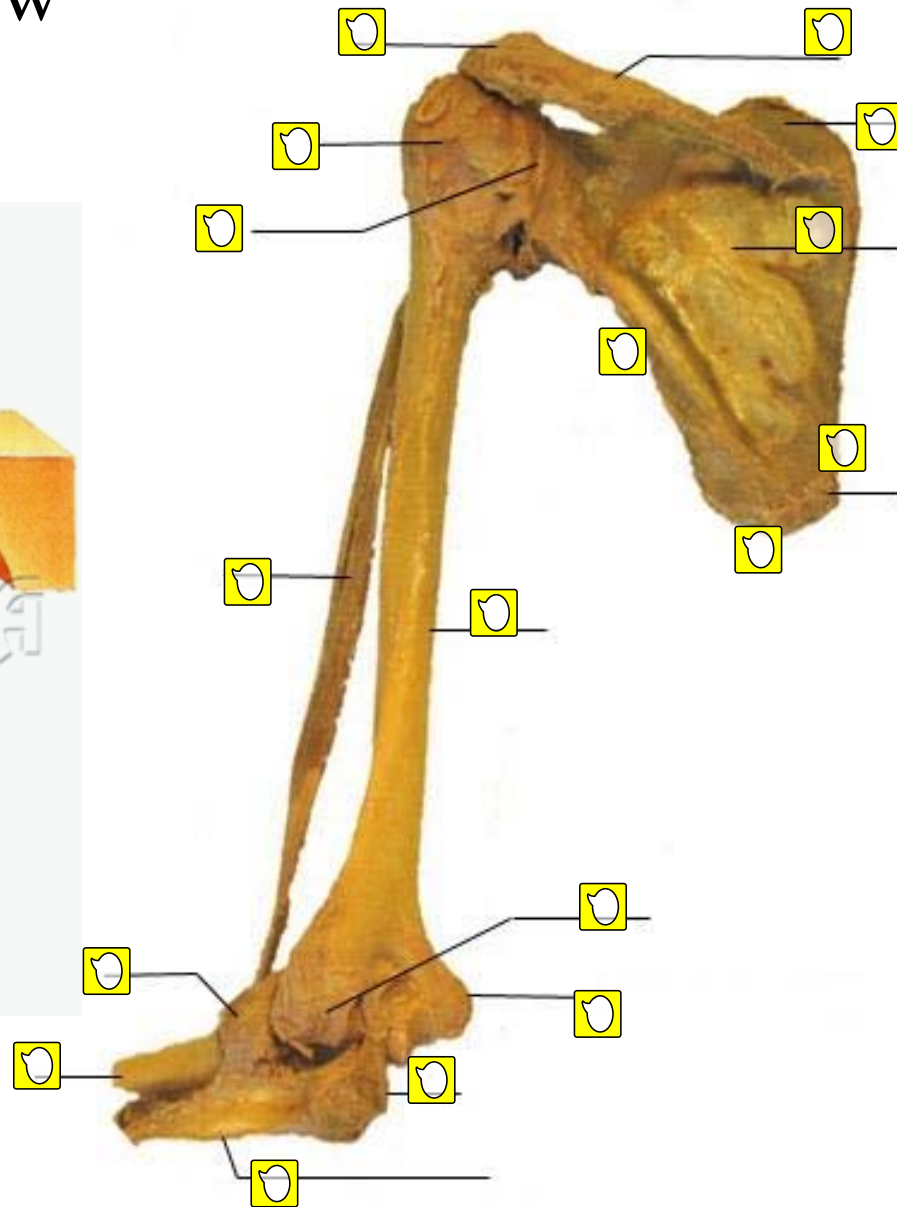
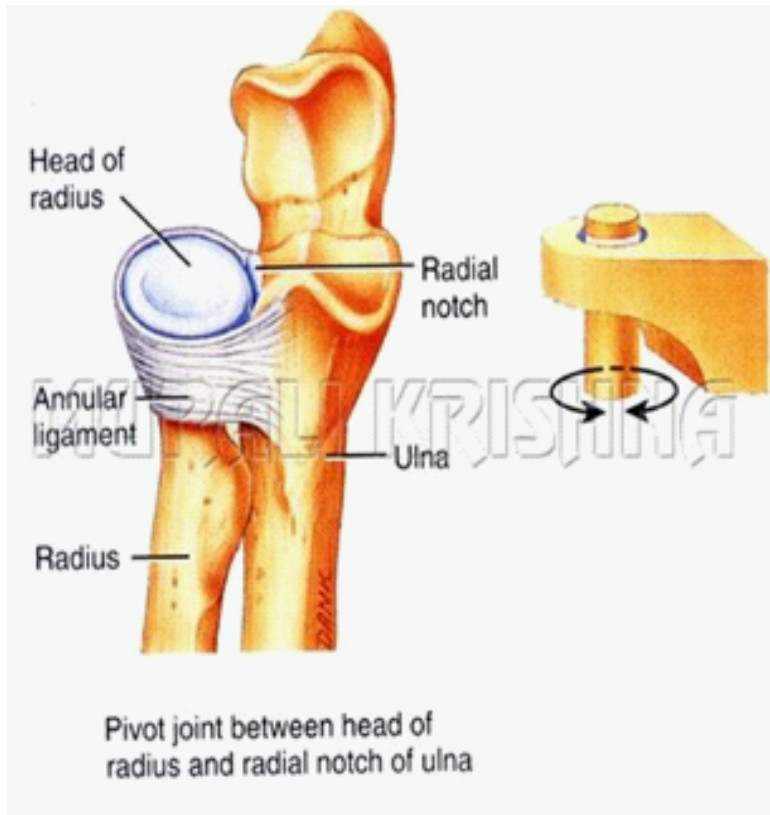
Shoulder and Elbow

Anterior View



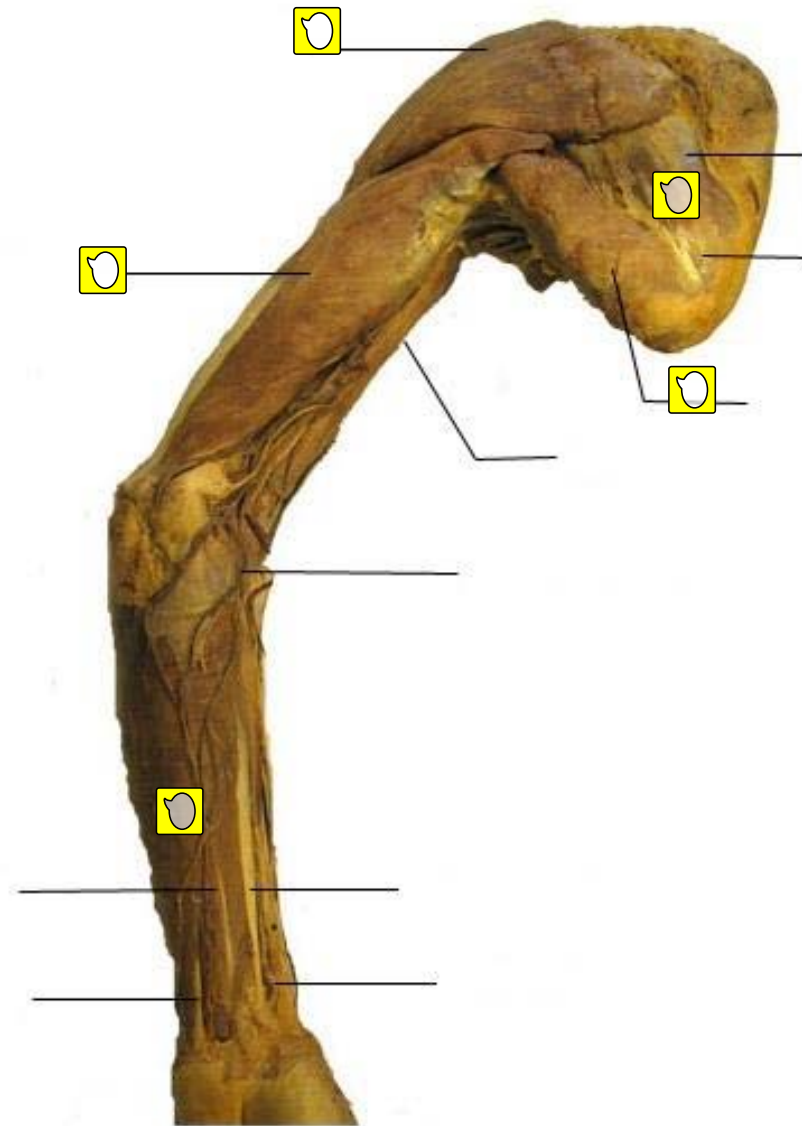
Shoulder and Elbow

Posterior View

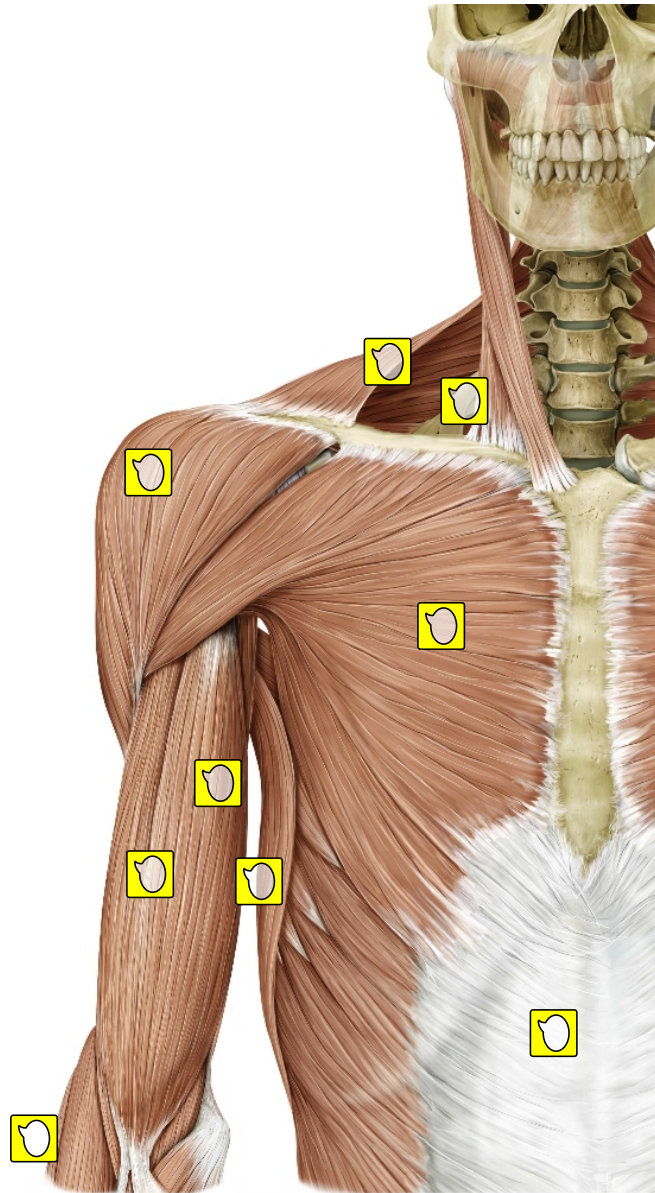


Arm

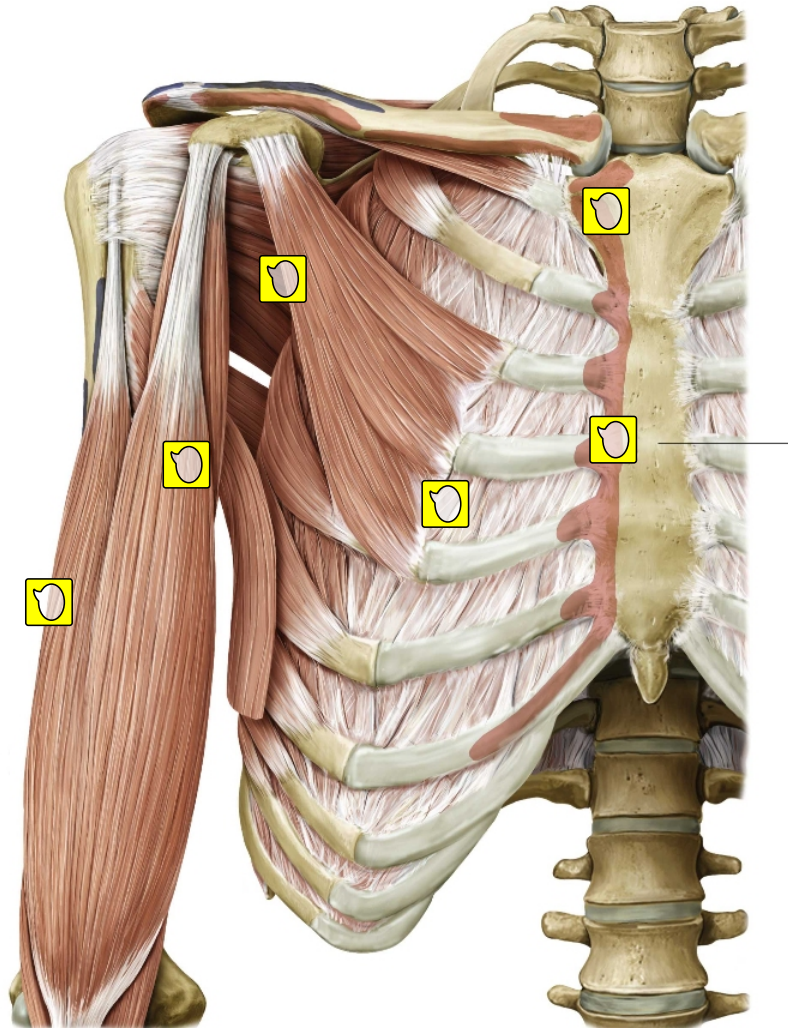
Posterior View



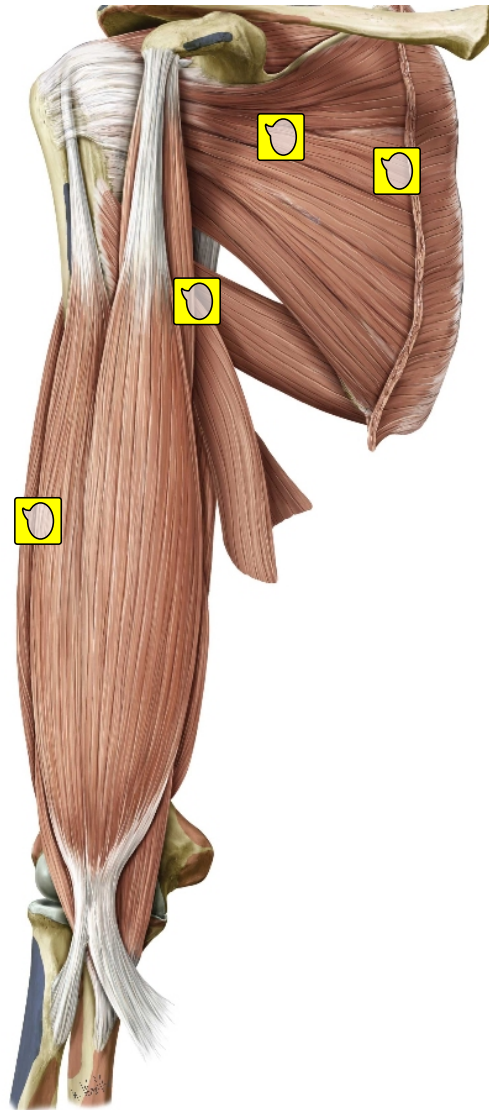
**Anterior muscles of the shoulder and arm.
Right side, anterior view. Superficial dissection.**



Anterior muscles of the shoulder and arm. Right side, anterior view. Deep dissection.



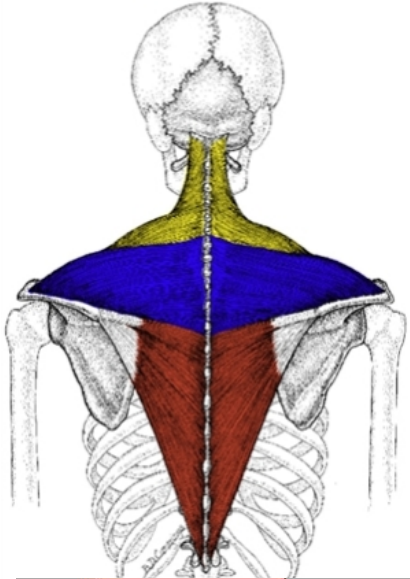
Anterior dissection of the shoulder and arm. Right arm, anterior view.



Posterior muscles of the shoulder and arm. Superficial dissection. Right side, posterior view.

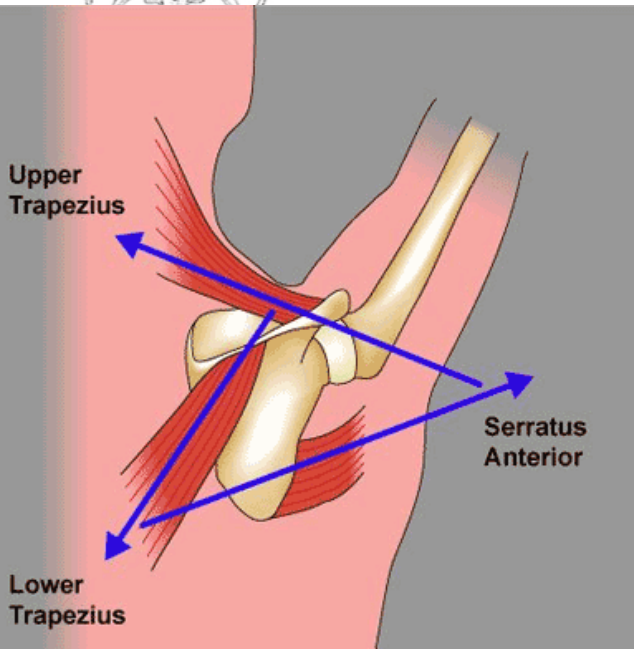
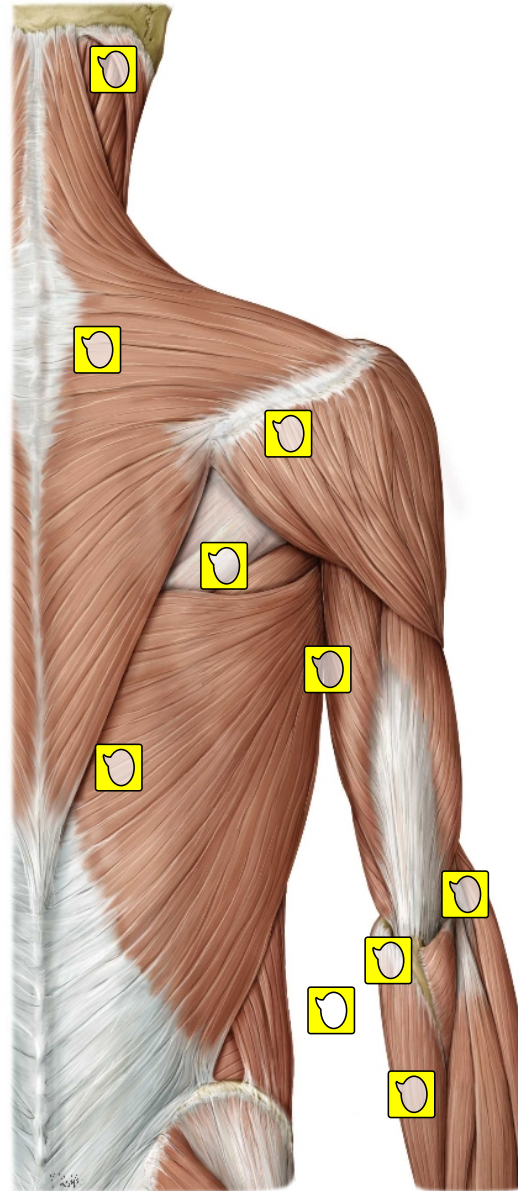
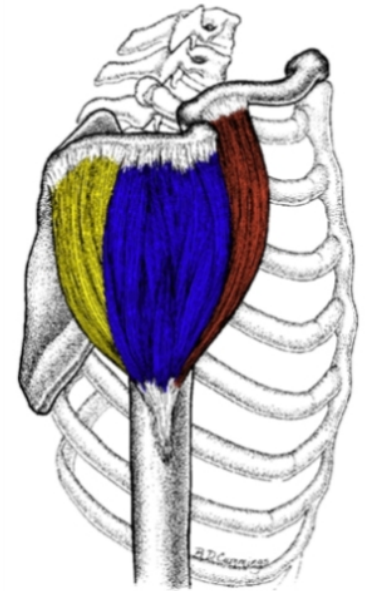
TRAPEZIUS

Lower Fibers
Middle Fibers
Upper Fibers

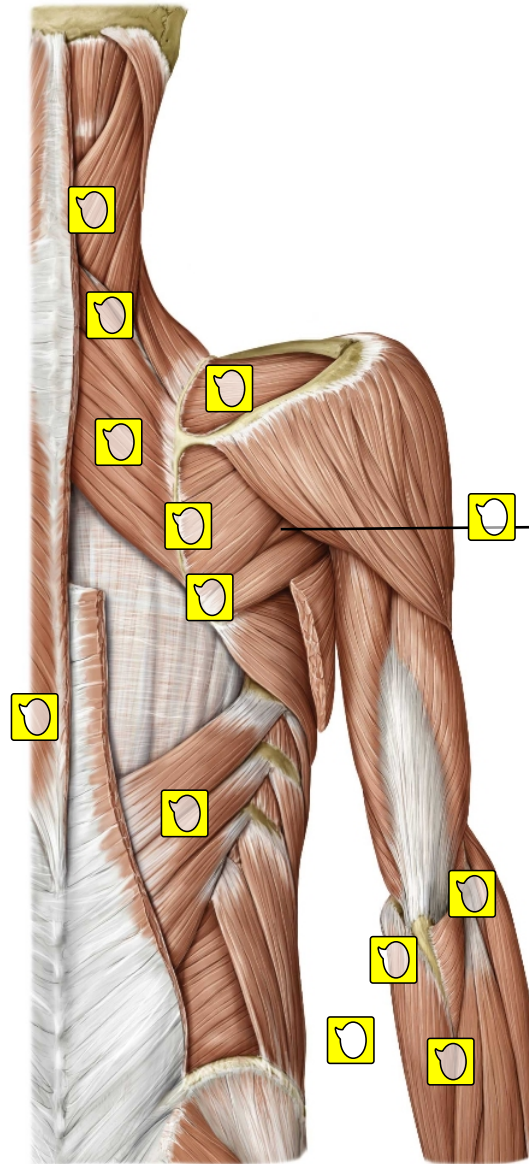


DELTOIDS

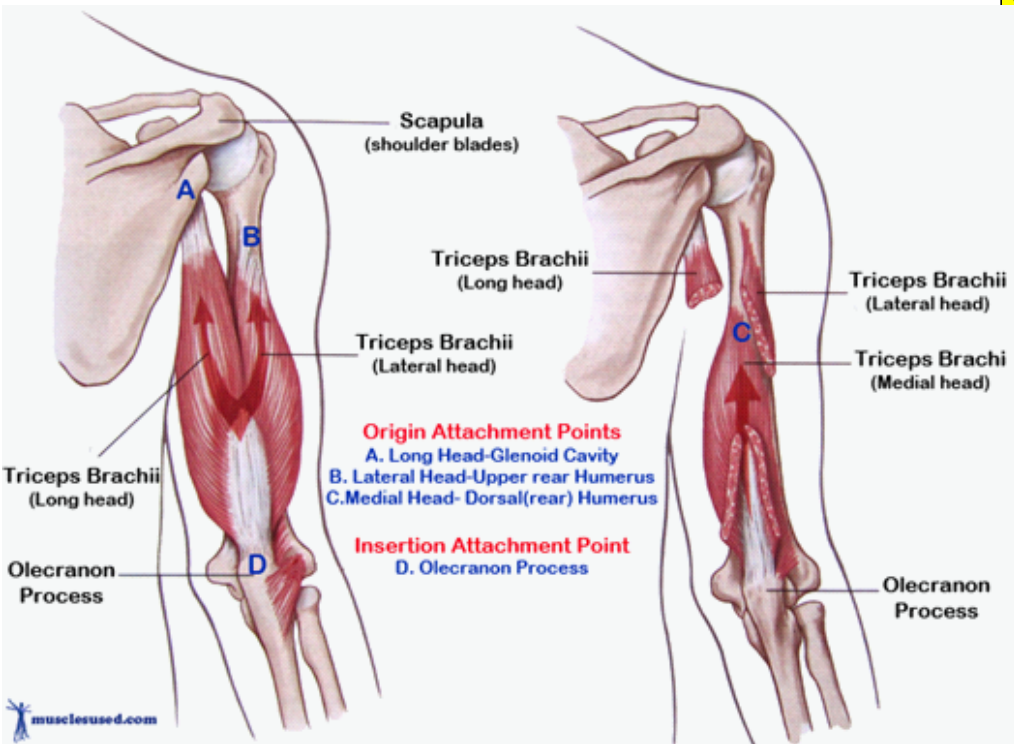
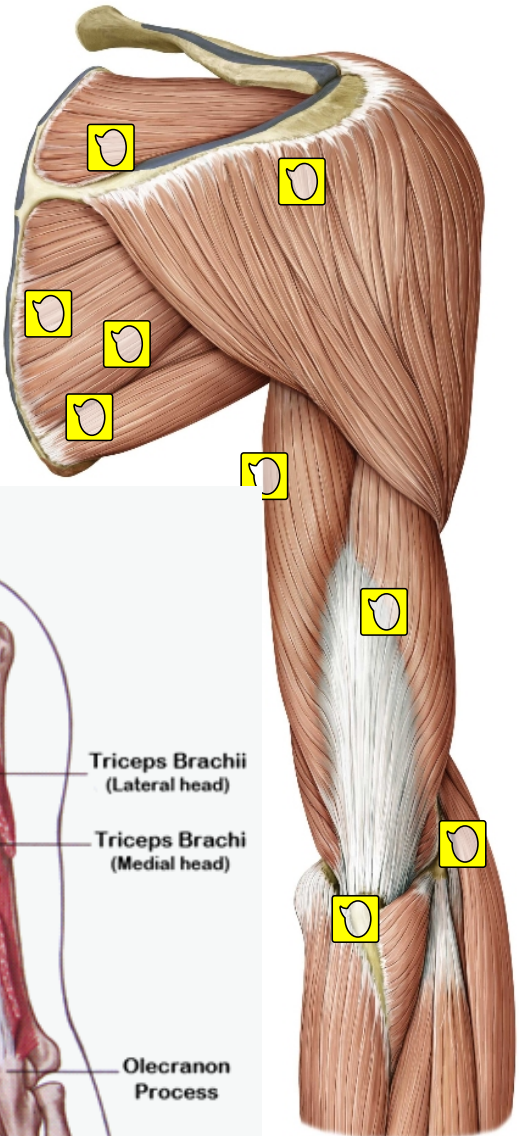
Anterior Deltoids
Lateral Deltoid
Posterior Deltoid



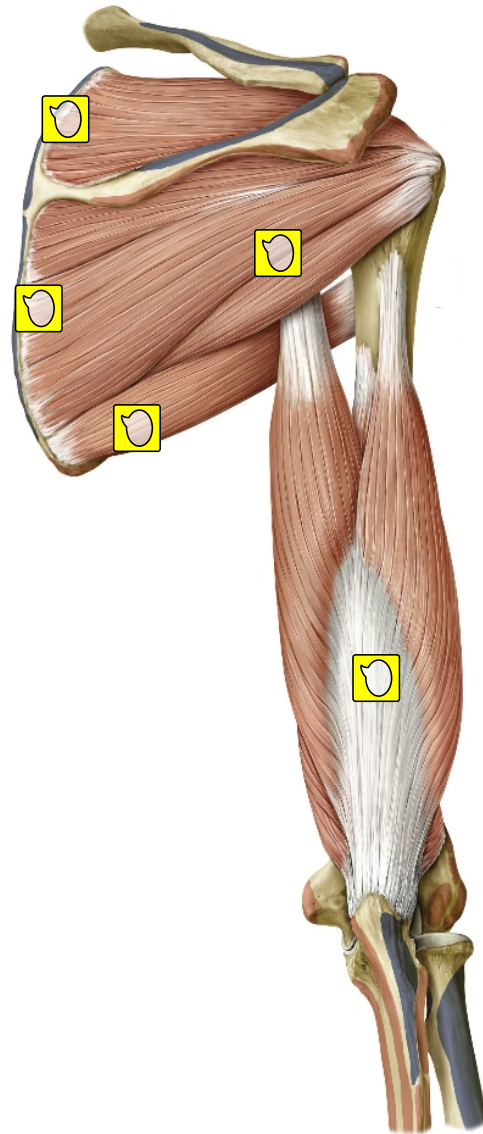
Posterior muscles of the shoulder and arm. Deep dissection. Right side, posterior view.



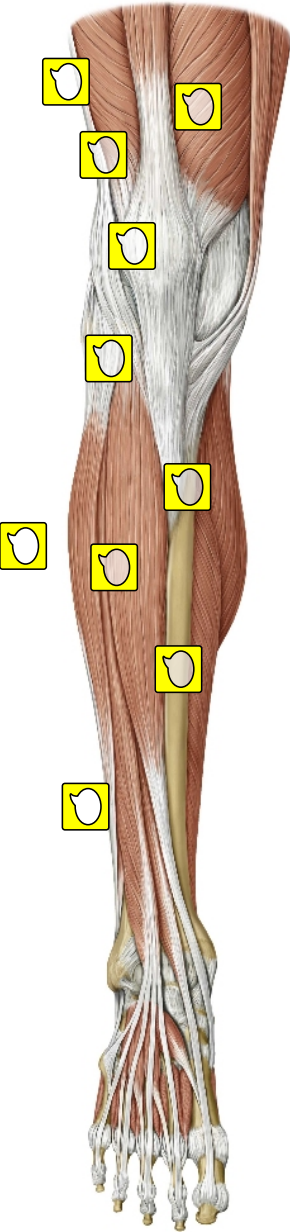
Posterior dissection of the shoulder and arm. Right arm, posterior view.



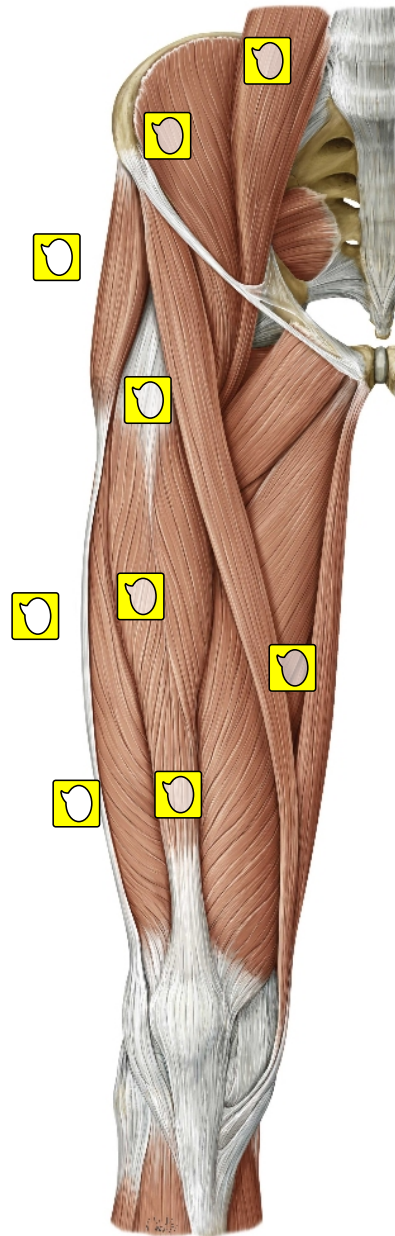
Posterior dissection of the shoulder and arm. Right arm, posterior view.



Muscles of the leg: Anterior view. Right leg.

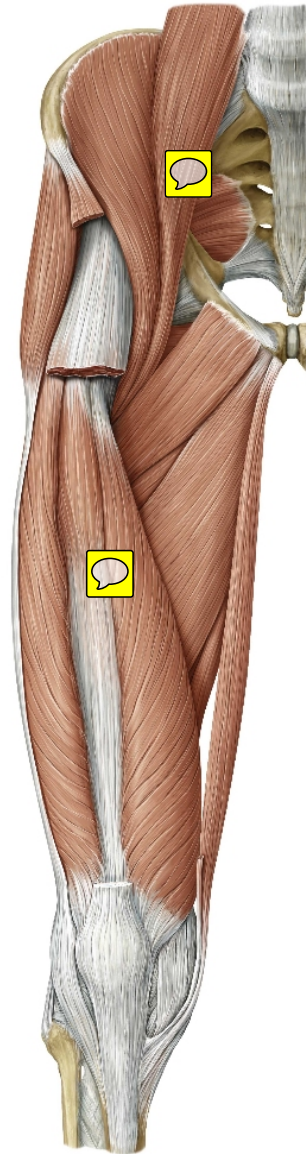


Muscles of the hip and thigh: Anterior view . Right limb.

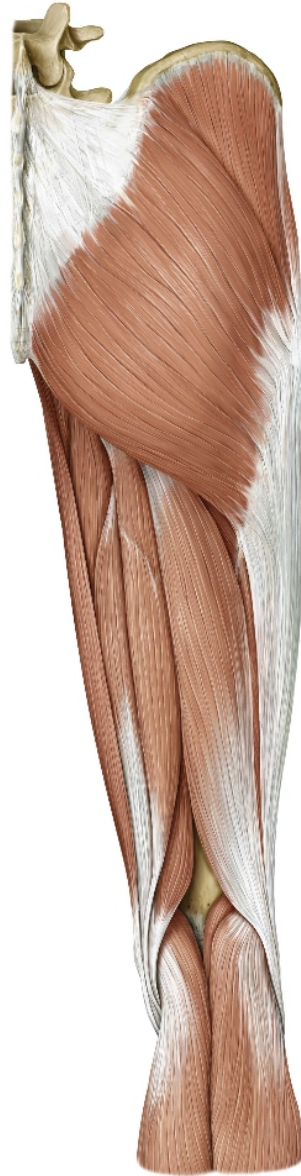


Muscles of the hip and thigh: Anterior view. Right limb.

Removed: Sartorius and rectus femoris.



Muscles of the hip, thigh, and gluteal region: Posterior view. Right limb.



Muscles of the leg: Posterior view. Right leg.

