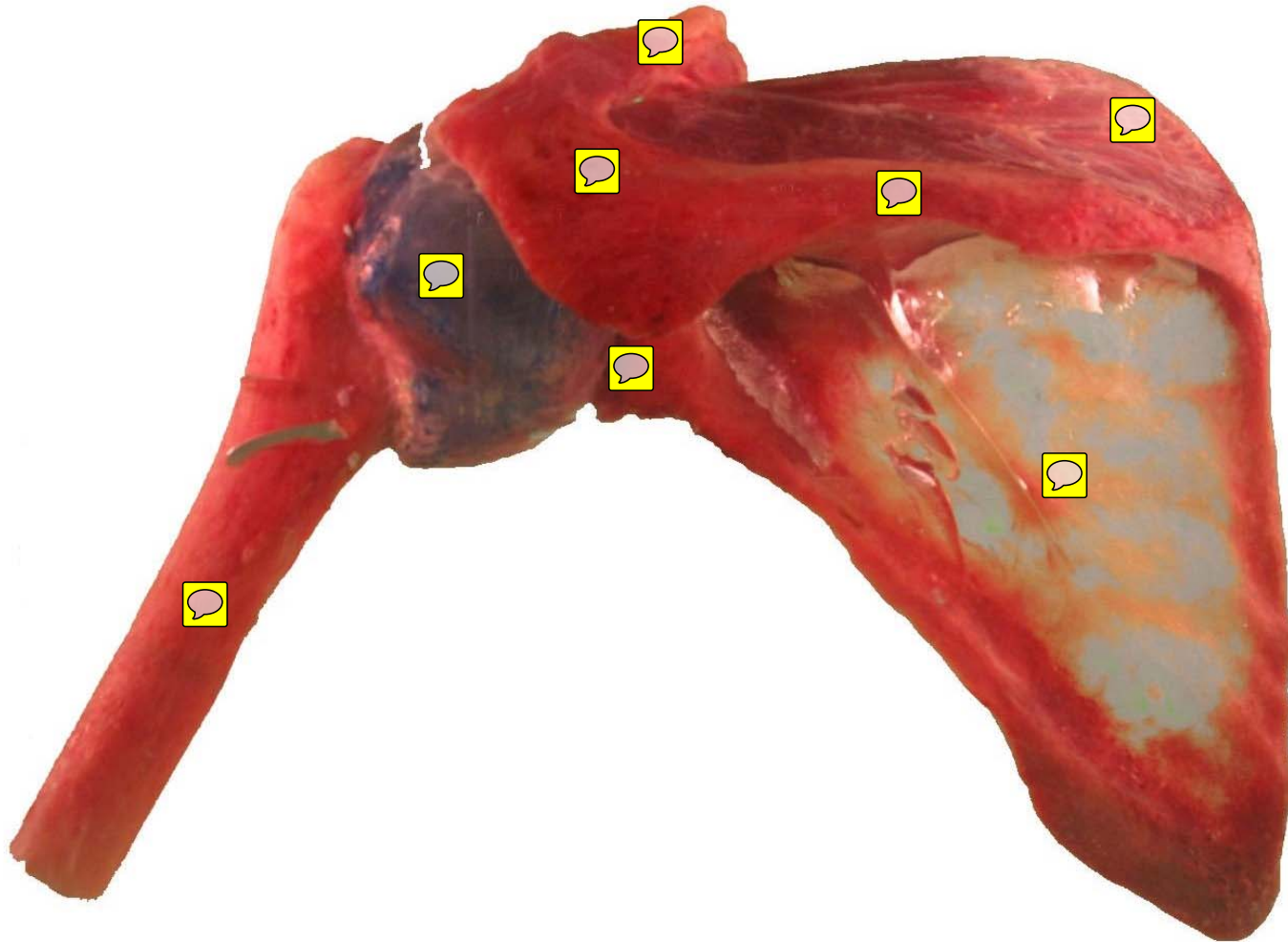


Lab 4

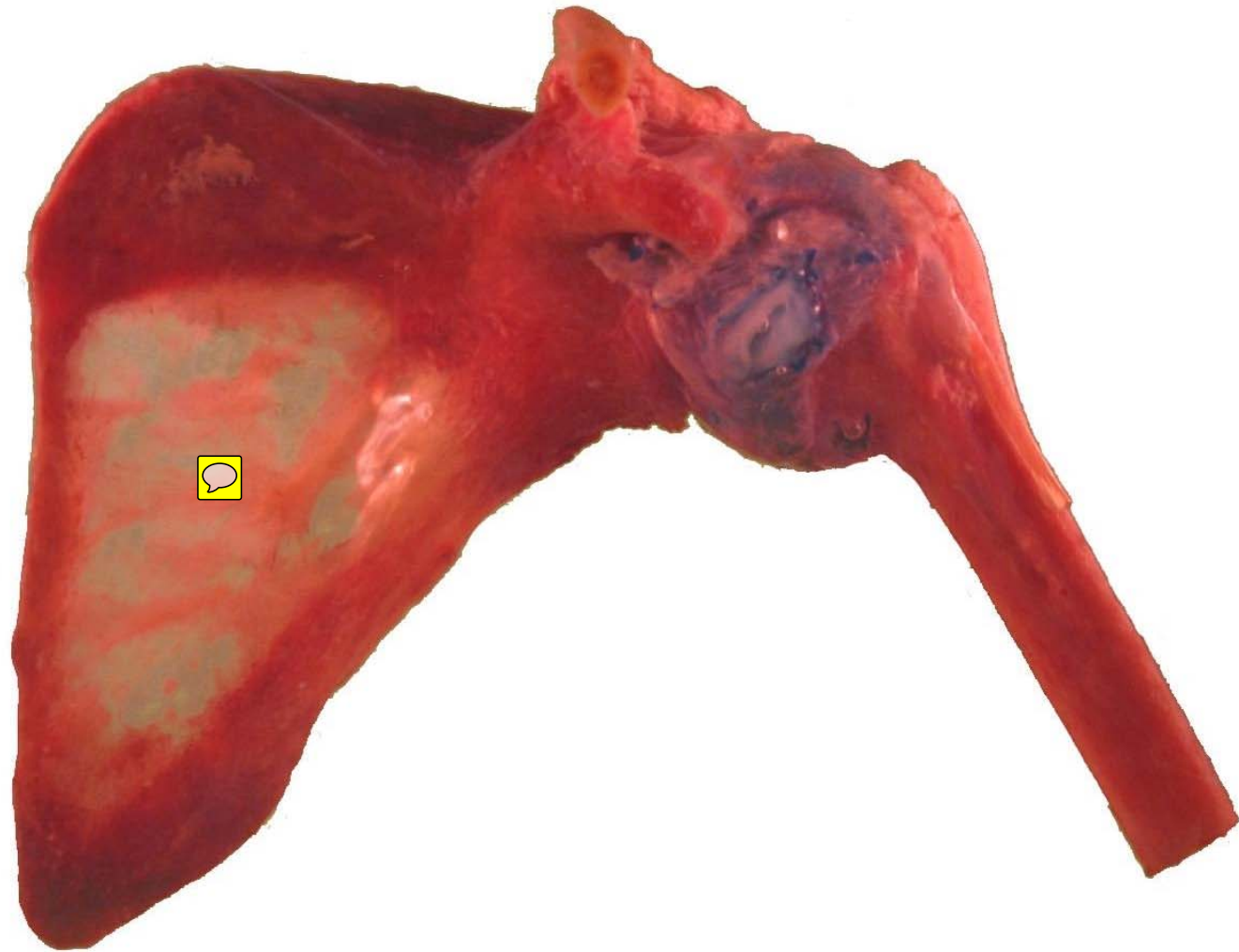
Bones and Joints

Lab Images

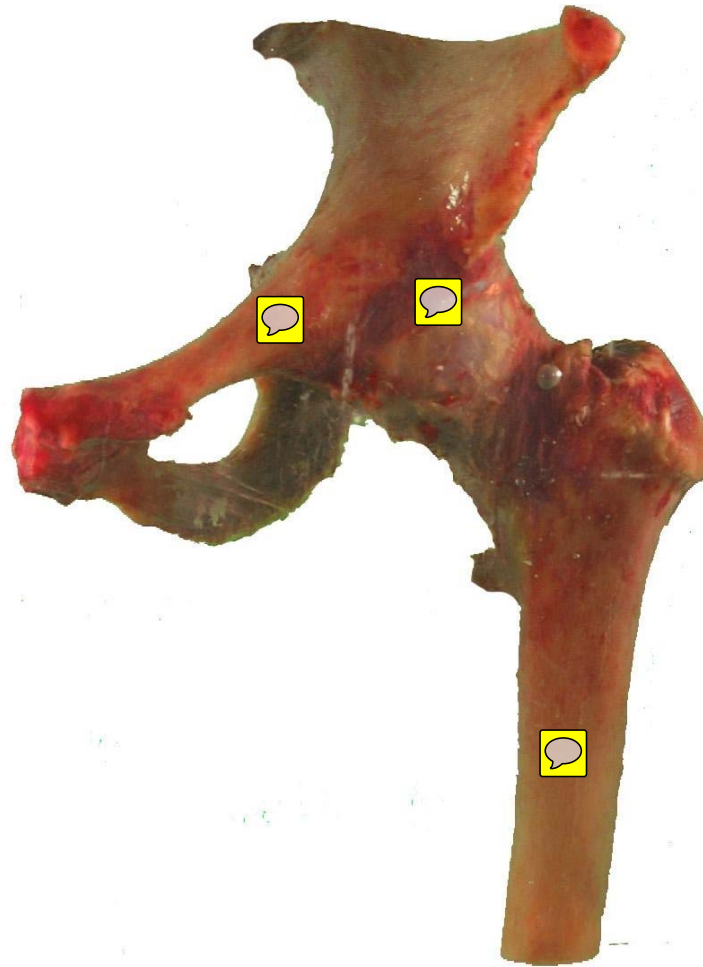
Shoulder – Posterior View



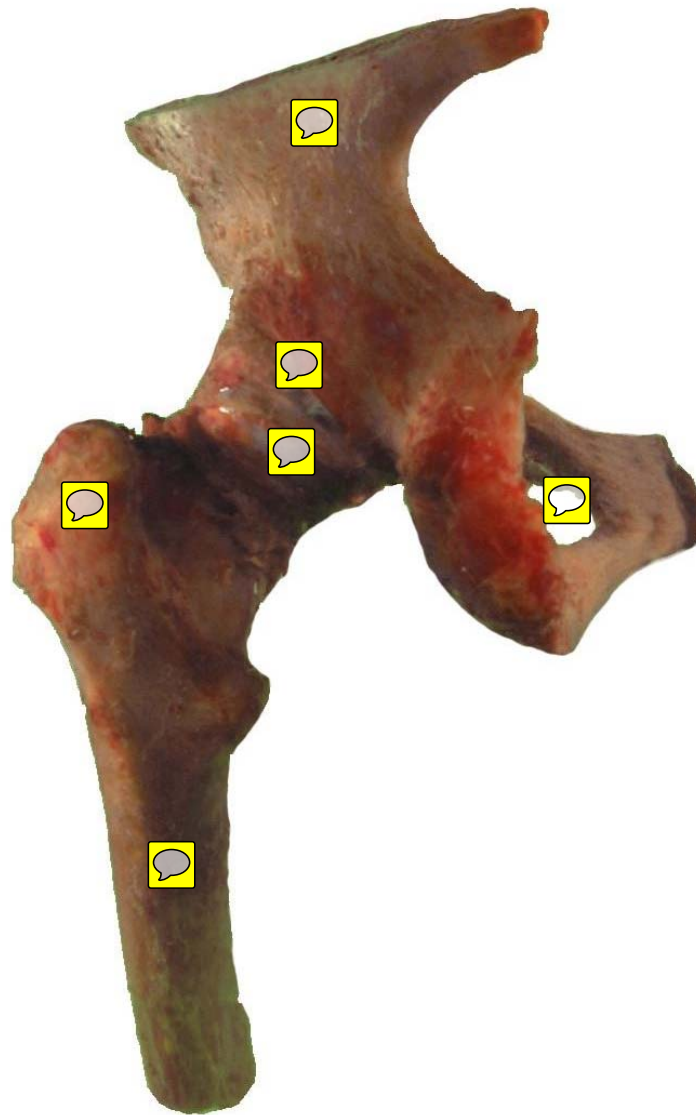
Shoulder – Anterior View



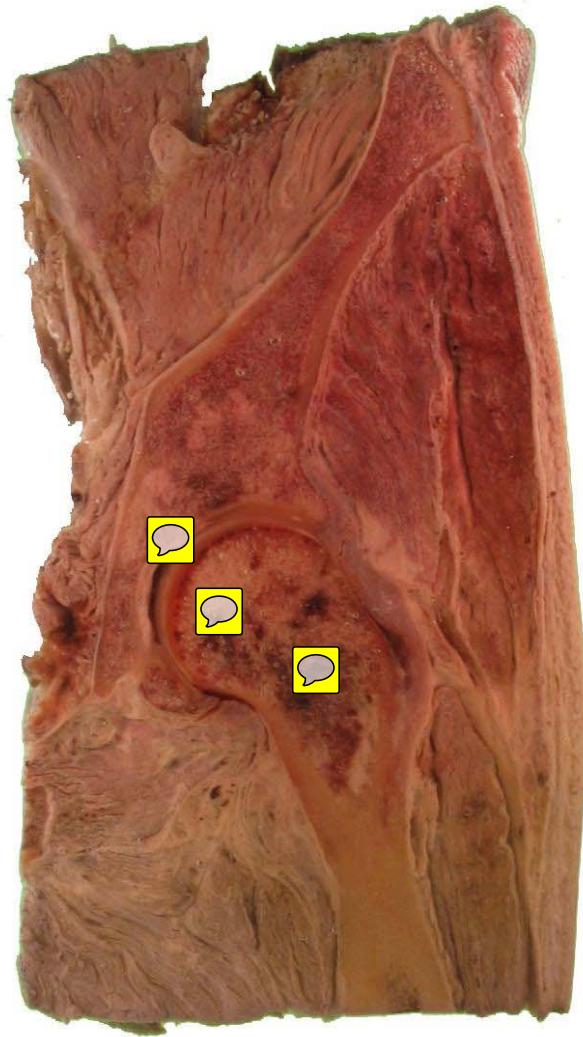
Hip – Anterior View



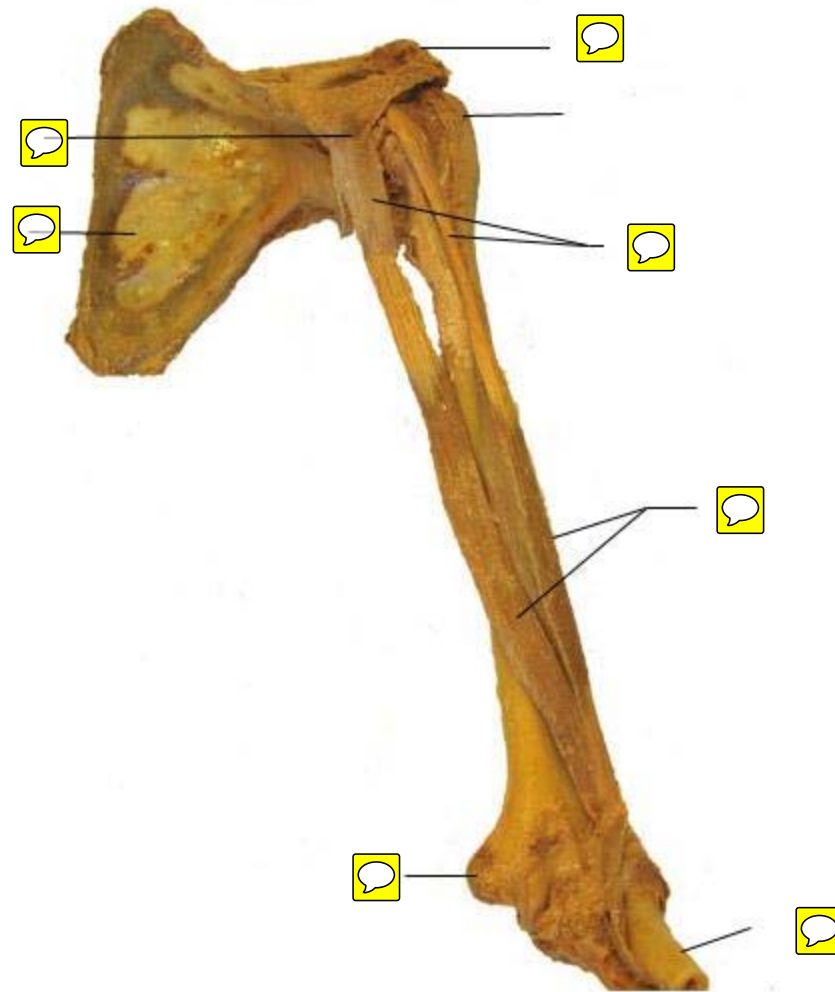
Hip – Posterior View



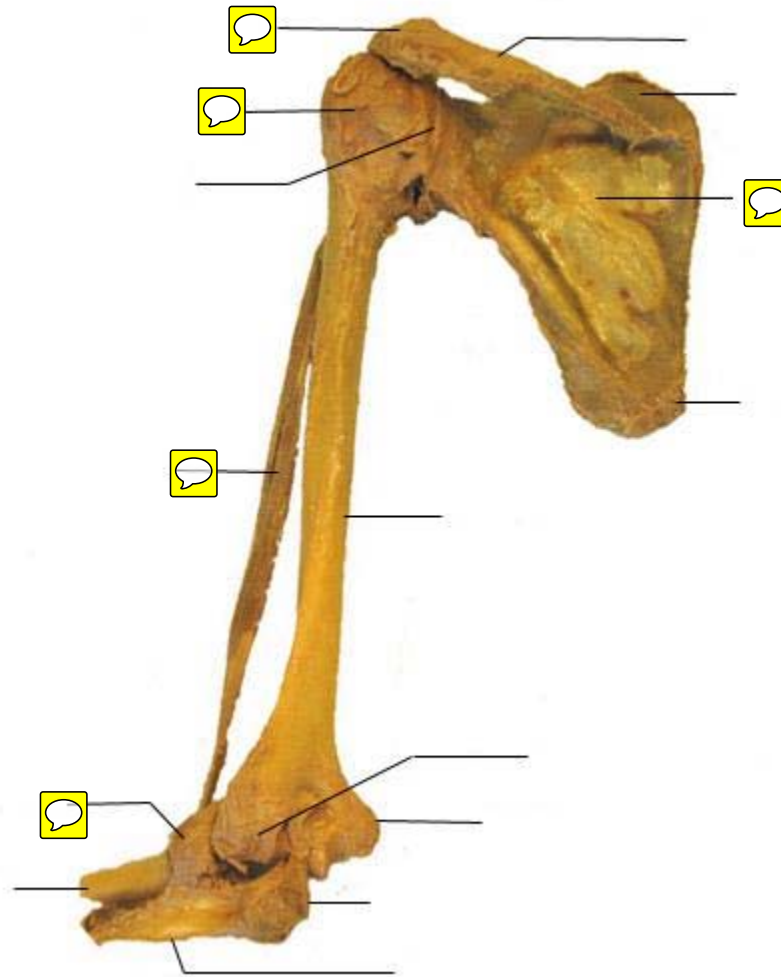
Hip – frontal section



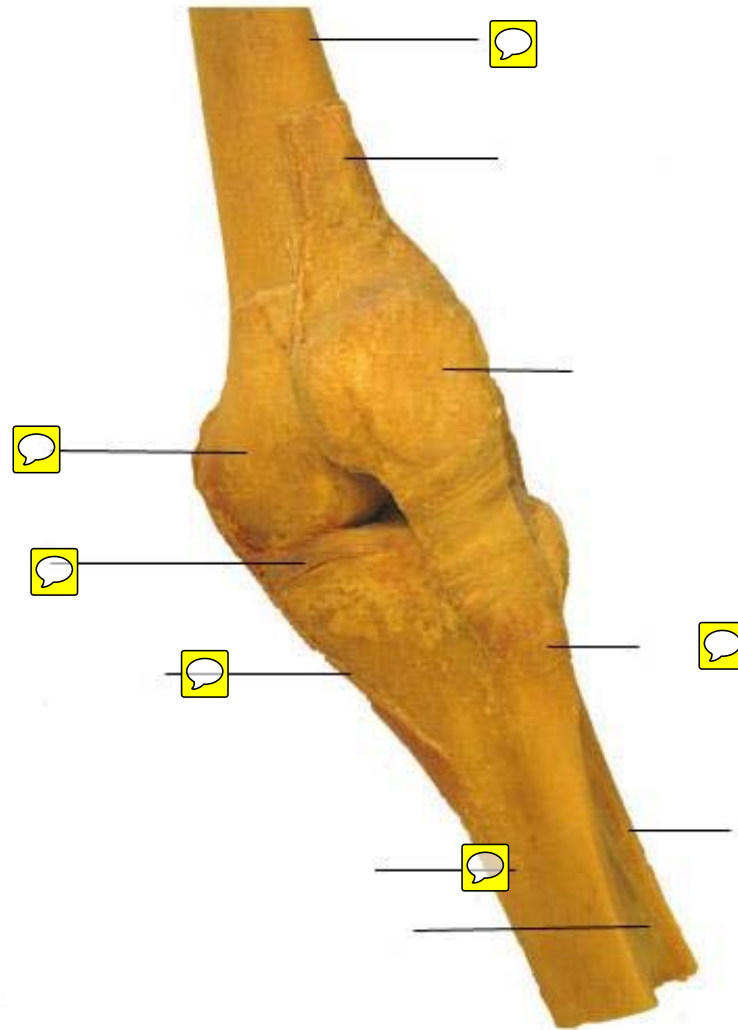
Shoulder and Elbow – Anterior View



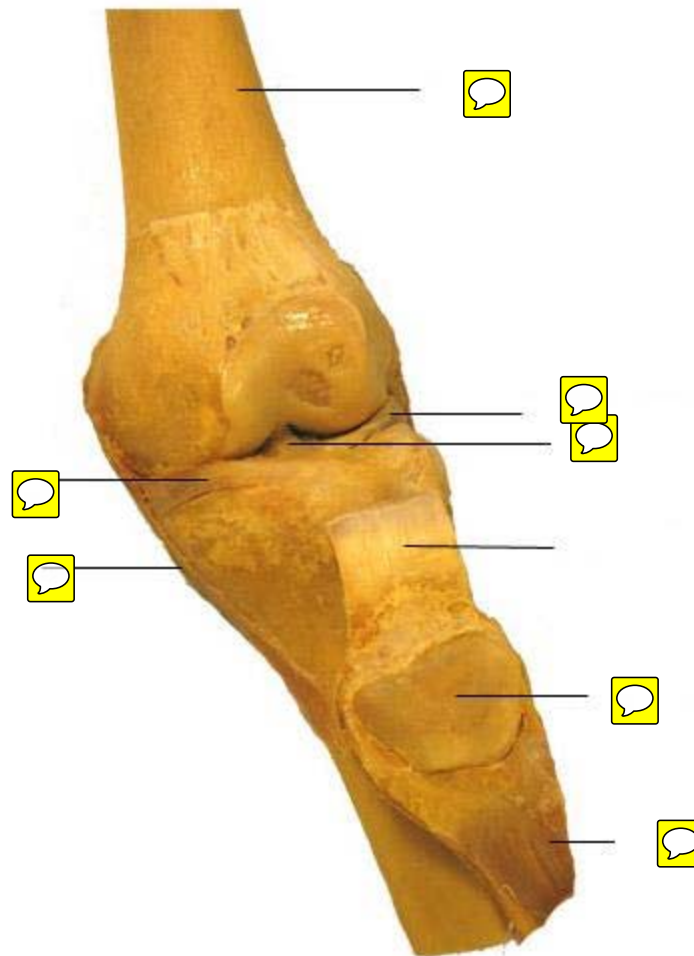
Shoulder and Elbow – Posterior View



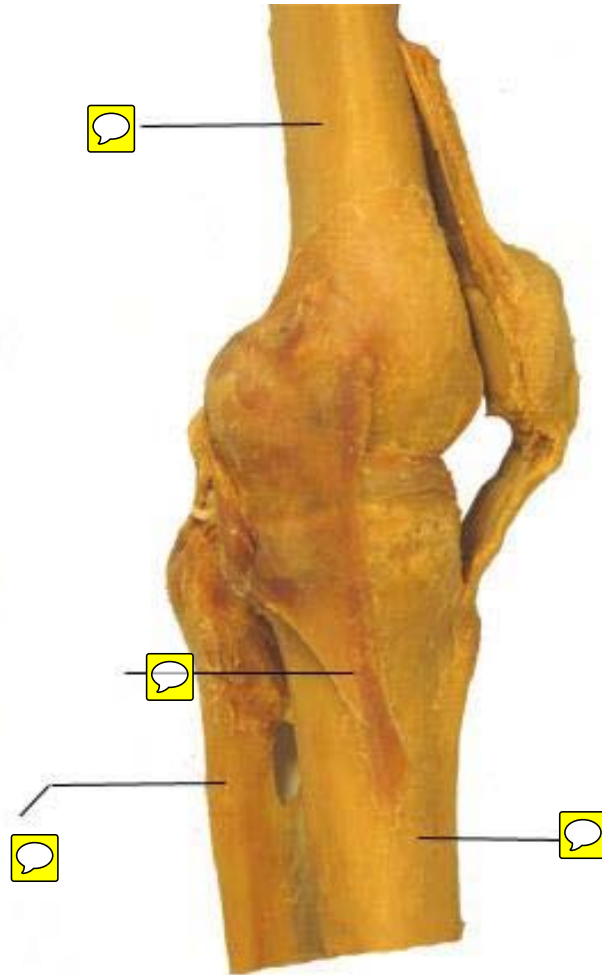
Knee – Anterior View



Knee – Anterior View – patella removed

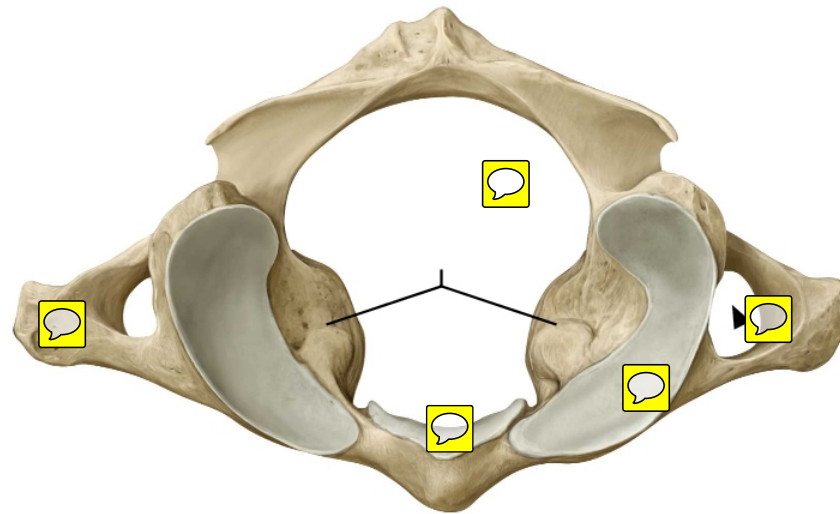


Knee – Medial View



Cervical Vertebrae: Atlas (C1)

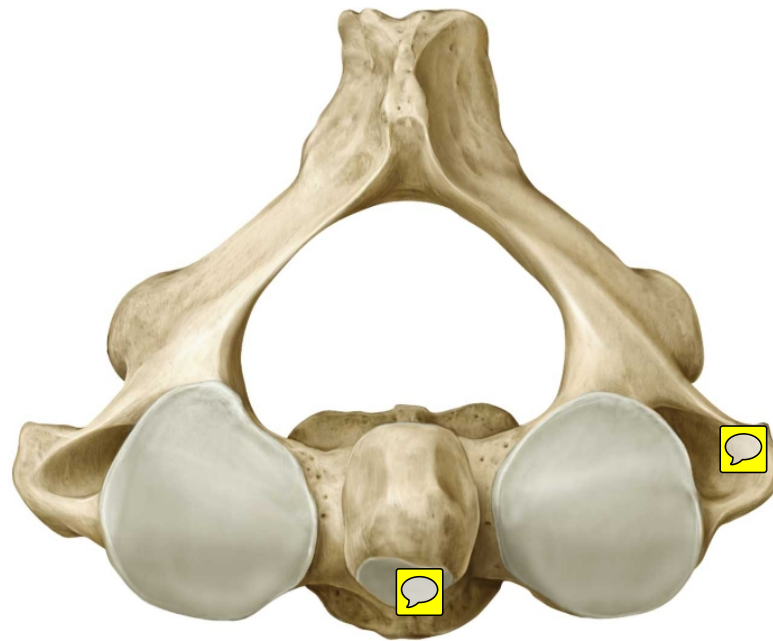
Superior view.



Copyright ©2008-2010 by Thieme. All rights reserved.
Illustrator: Karl Wesker

Axis (C2)

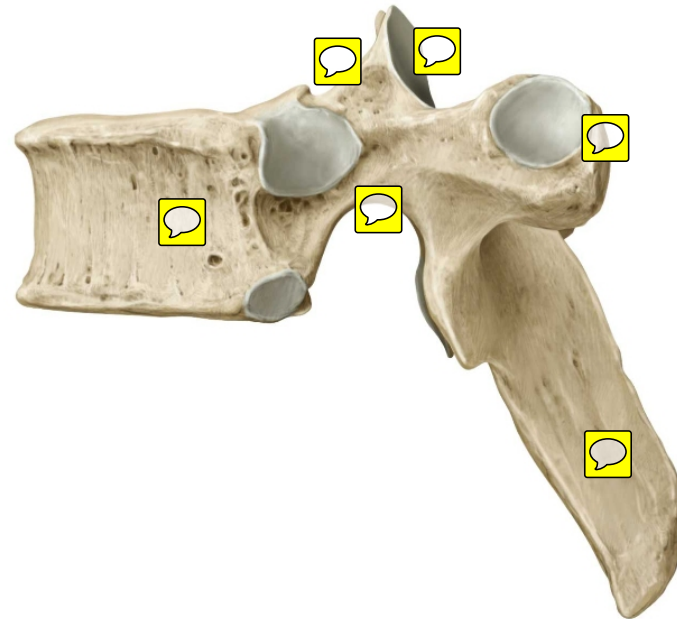
Cervical Vertebrae: Superior view.



Copyright ©2008-2010 by Thieme. All rights reserved.
Author: Karl Wesker

Typical thoracic vertebra (T6)

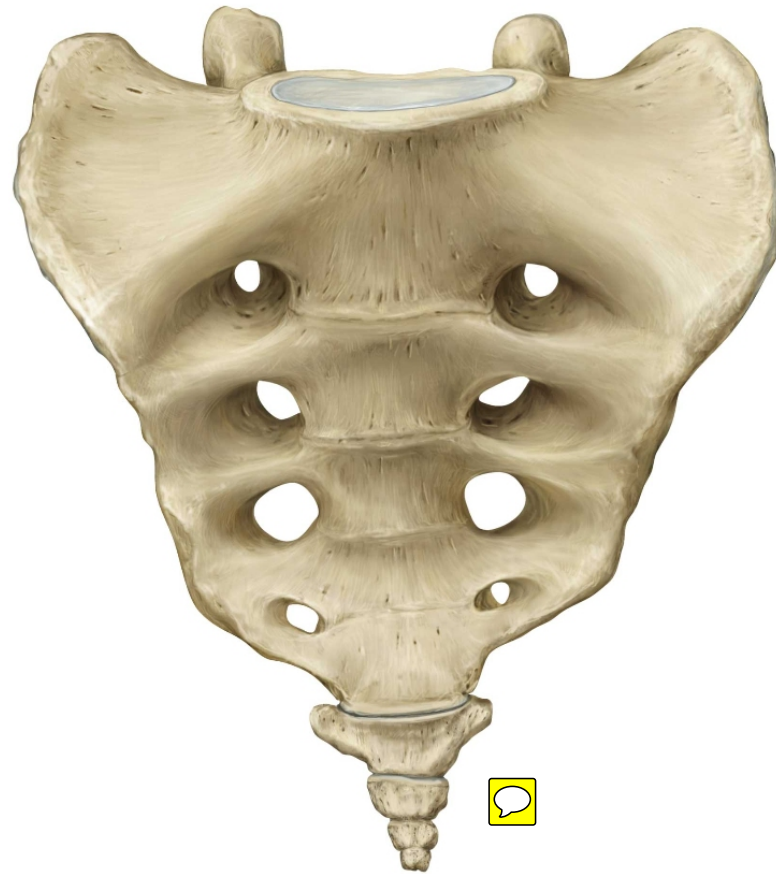
Left lateral view.



Copyright ©2008-2010 by Thieme. All rights reserved.
Illustrator: Karl Wesker

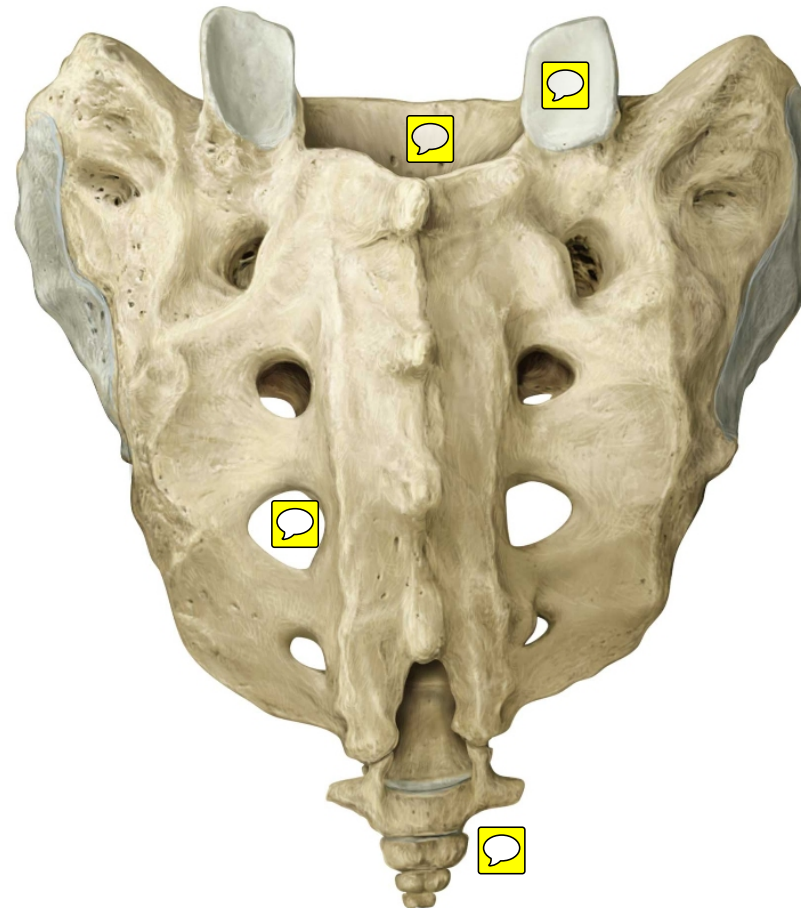
Sacrum and coccyx

Anterior view.



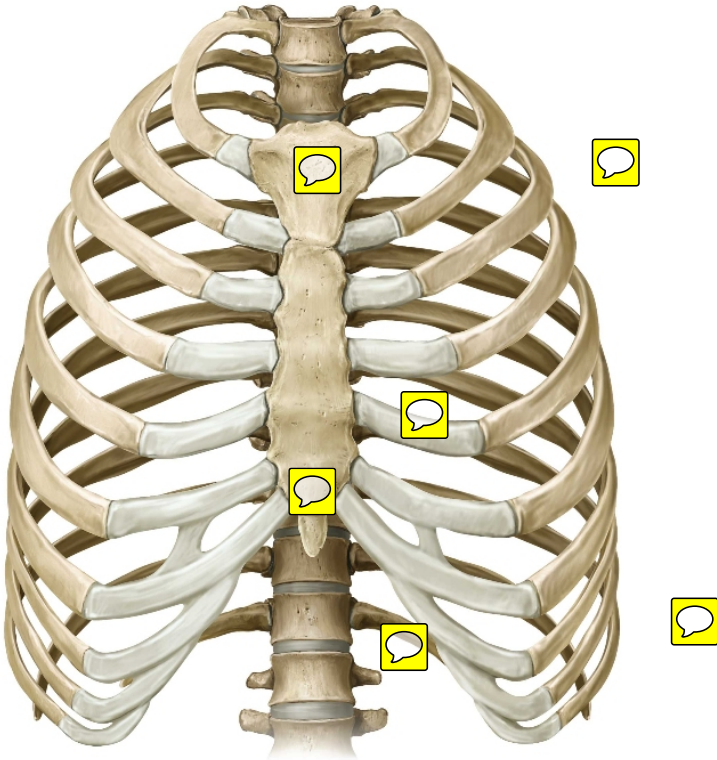
Sacrum and coccyx

Posterior view.



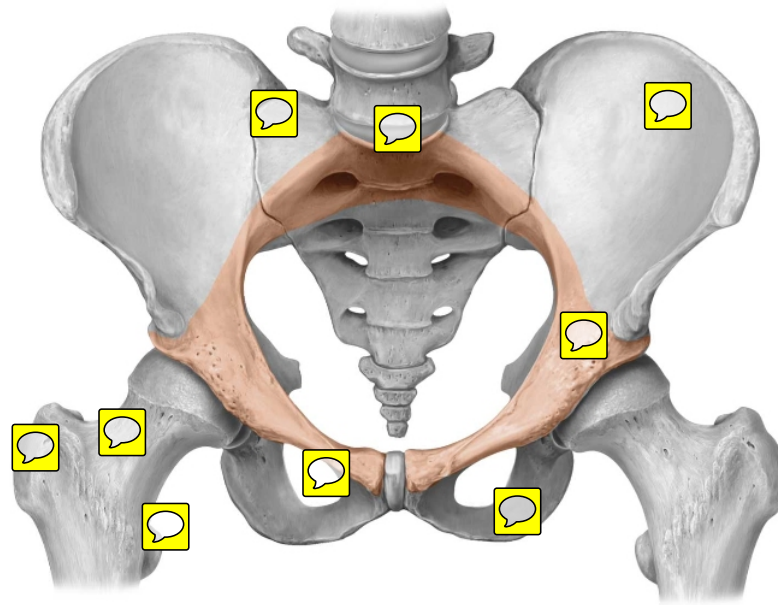
Thoracic skeleton

Anterior view.



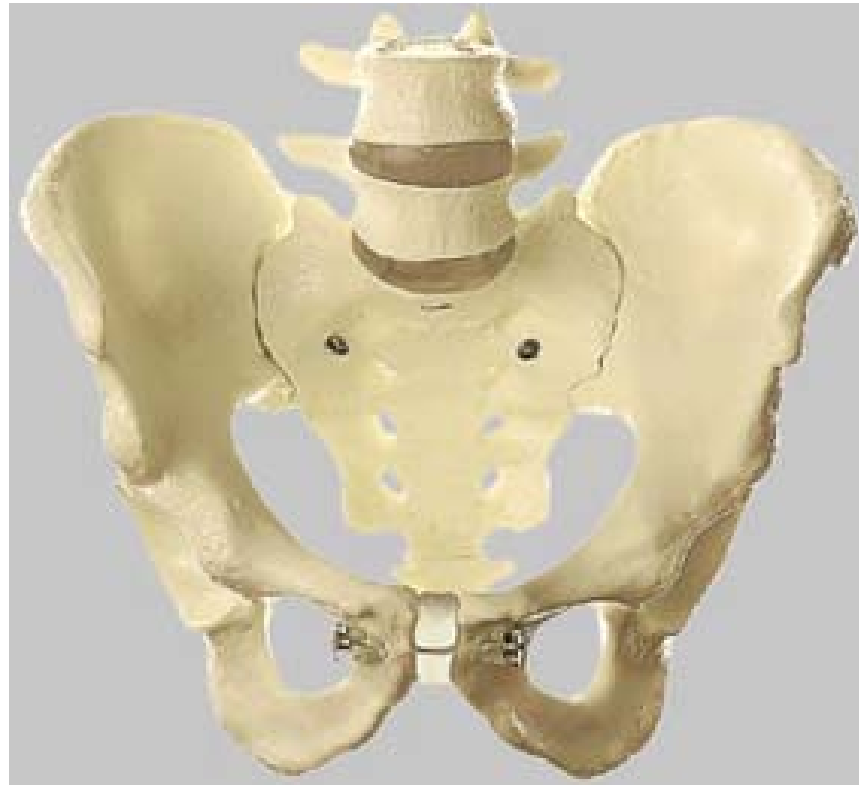Copyright ©2008-2010 by Thieme. All rights reserved.
Illustrator: Karl Wesker

Pelvic girdle. Anterosuperior view.



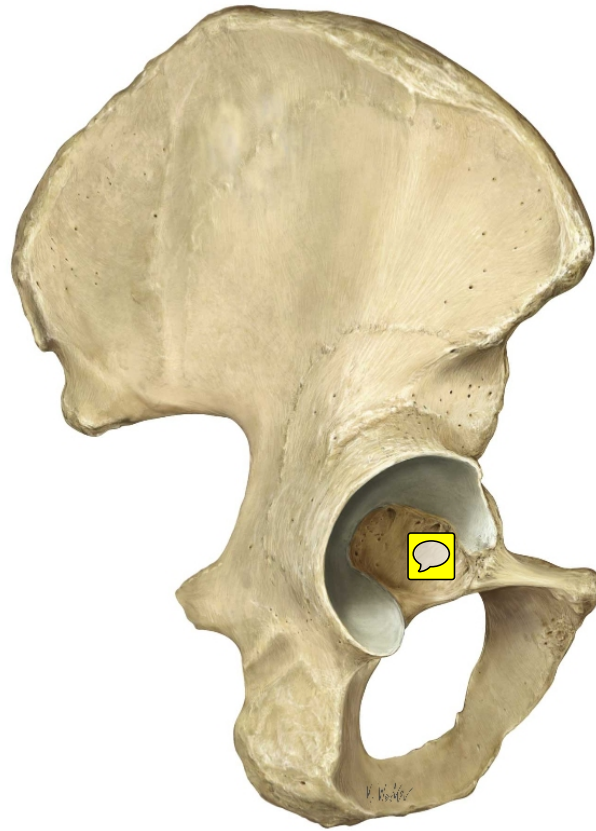Copyright ©2008-2010 by Thieme. All rights reserved.
Illustrator: Karl Wesker

Pelvis



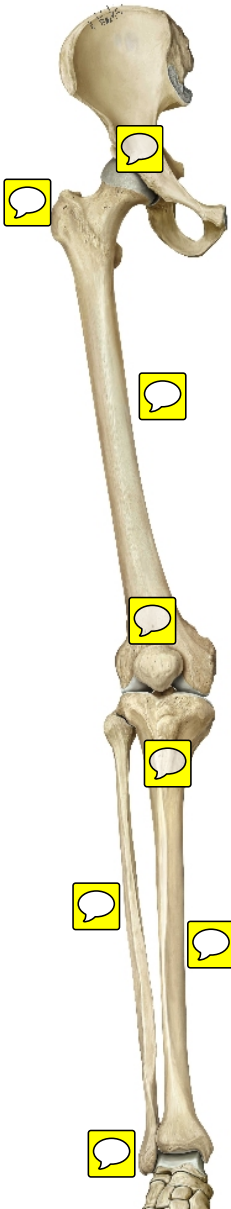
Hip bone: Lateral view.

Right hip bone (male).

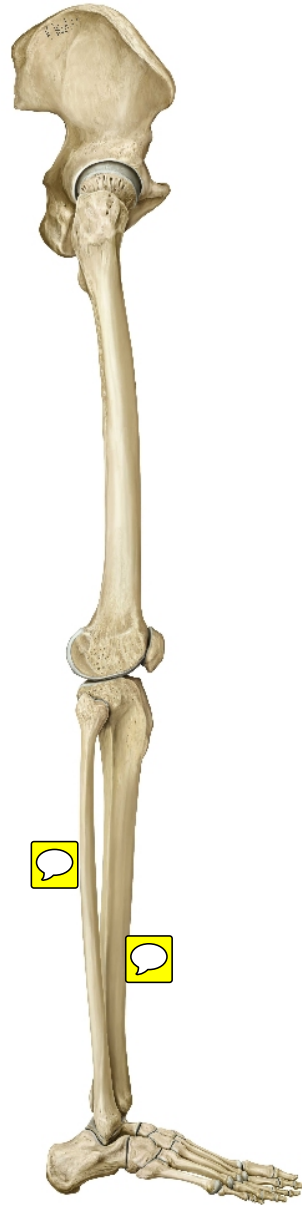

Copyright ©2008-2010 by Thieme. All rights reserved.
Illustrator: Karl Wesker

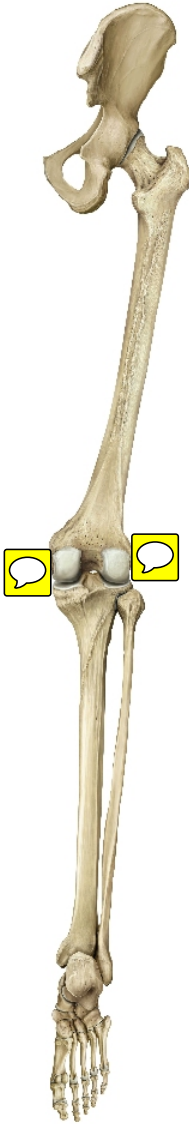
Bones of the lower limb. Right limb. Anterior view.



Bones of the lower limb. Right limb. Right lateral view.




Bones of the lower limb. Right limb. Posterior view.



Right femur

Anterior view.




Right femur
Posterior view.



Femur



Tibia and fibula. Right leg. Anterior view.



Copyright ©2008-2010 by Thieme. All rights reserved.
Illustrator: Karl Wasker

Tibia and fibula. Right leg.



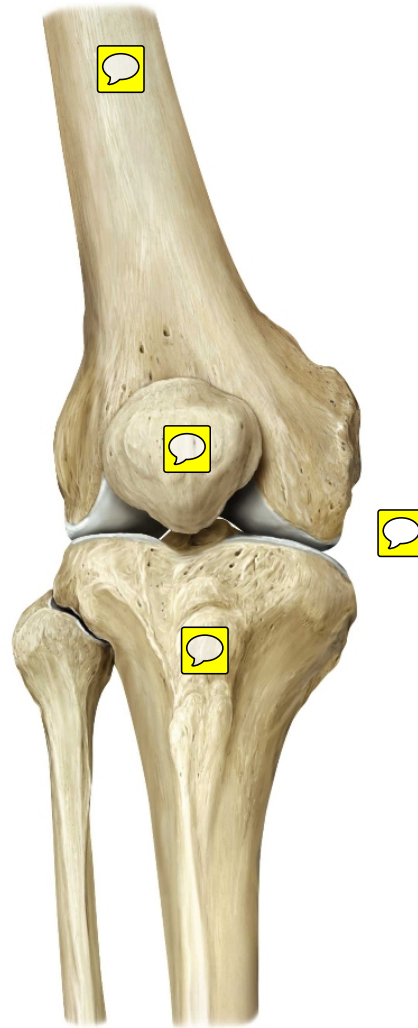
Copyright ©2008-2010 by Thieme. All rights reserved.
Illustrator: Karl Wesker

Tibia and fibula



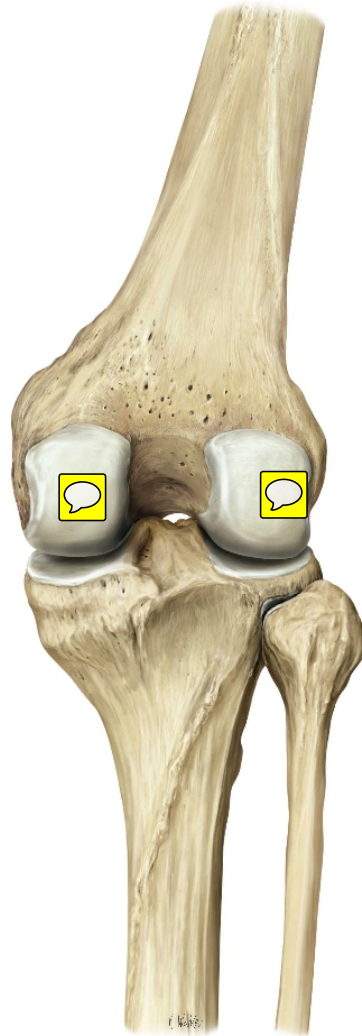
Right knee joint

Anterior view.



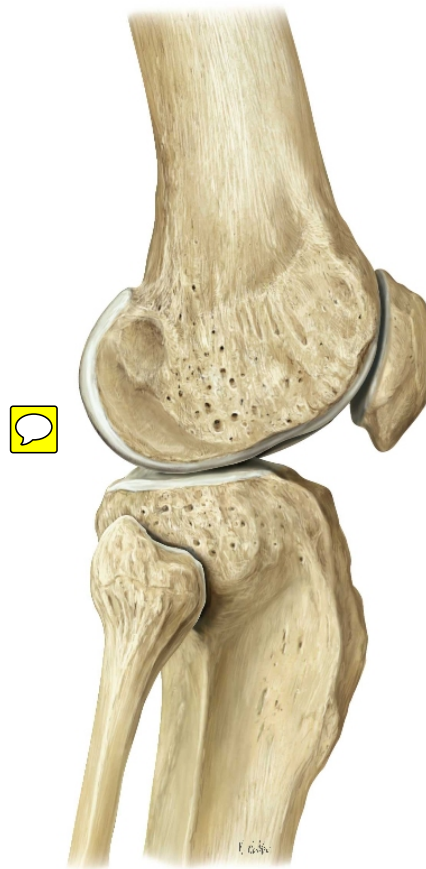
Right knee joint

Posterior view.

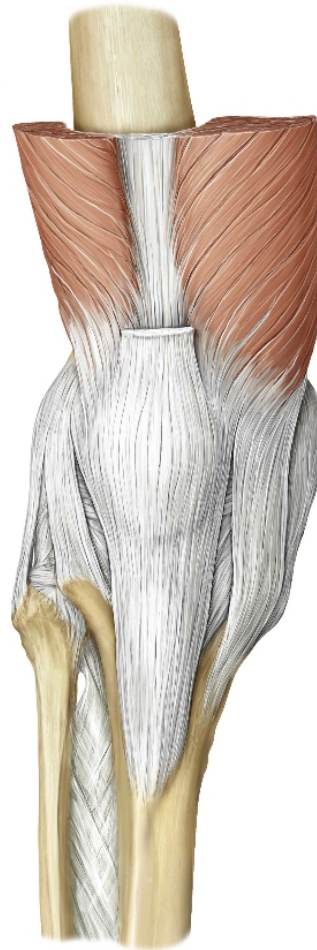

Right knee joint

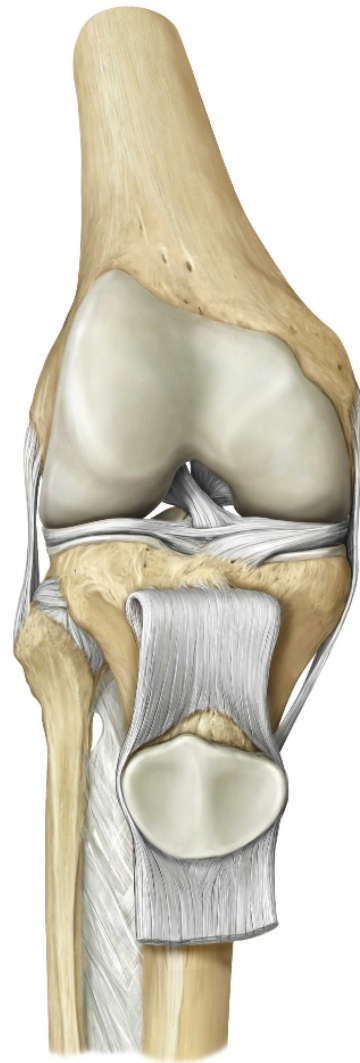
Lateral view.



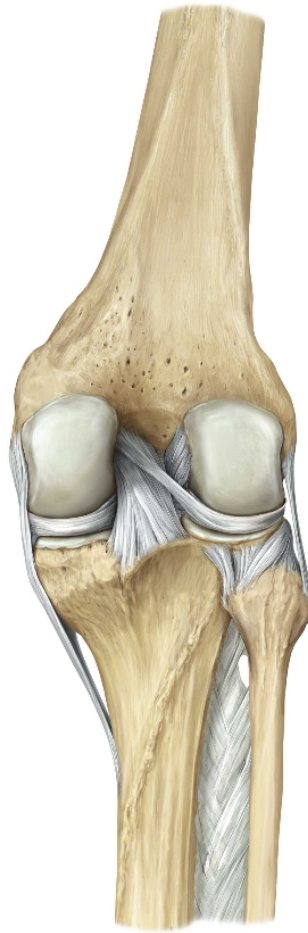
Ligaments of the knee joint. Anterior view of right knee.



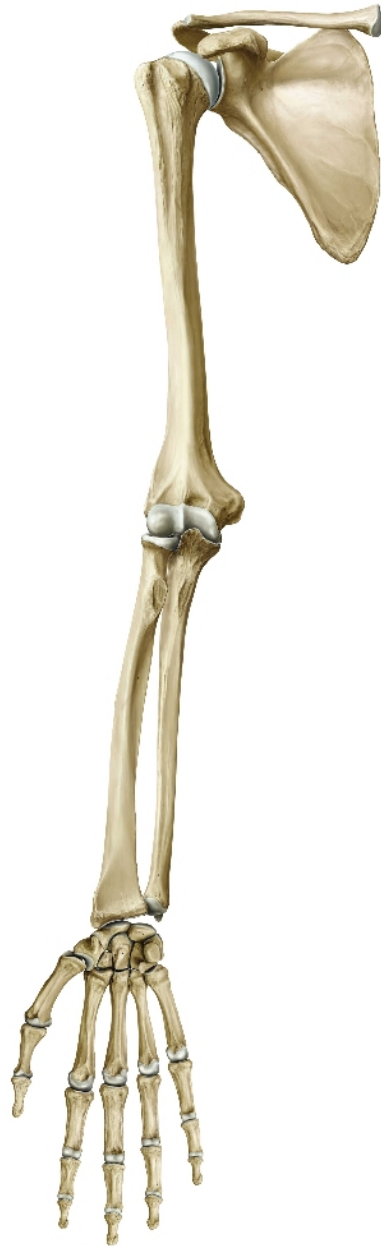Cruciate and collateral ligaments. Right knee joint. Anterior view.



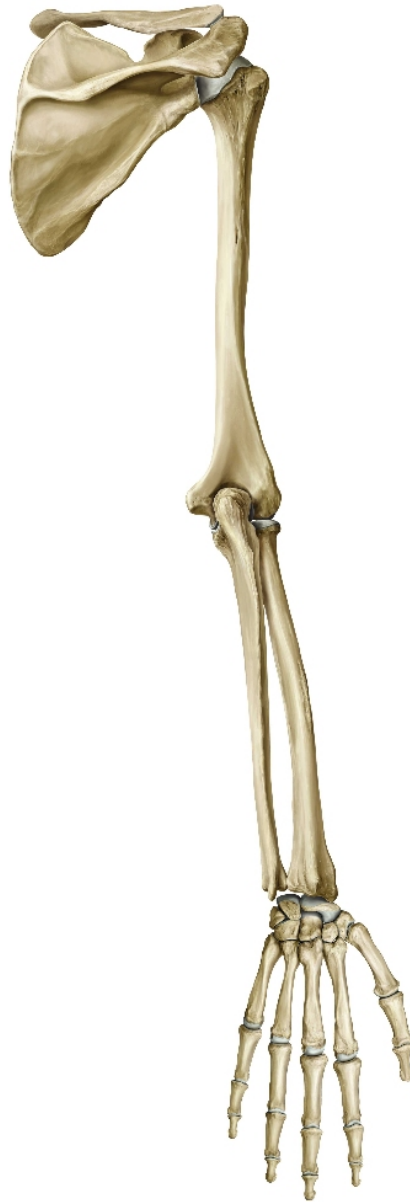Cruciate and collateral ligaments. Right knee joint. Posterior view.



Skeleton of the upper limb. Right limb. Anterior view.



Skeleton of the upper limb. Right limb. Posterior view



Clavicle.

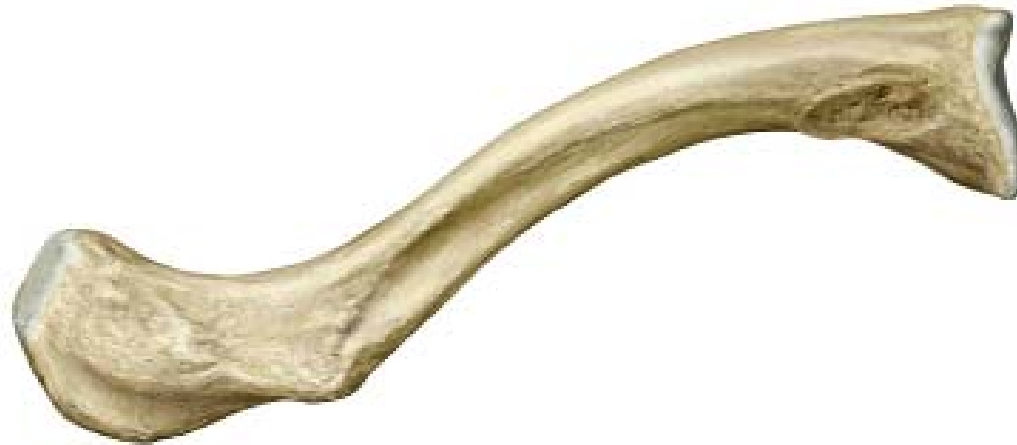Right clavicle. Superior view.



Copyright ©2008-2010 by Thieme. All rights reserved.
Illustrator: Karl Wesker

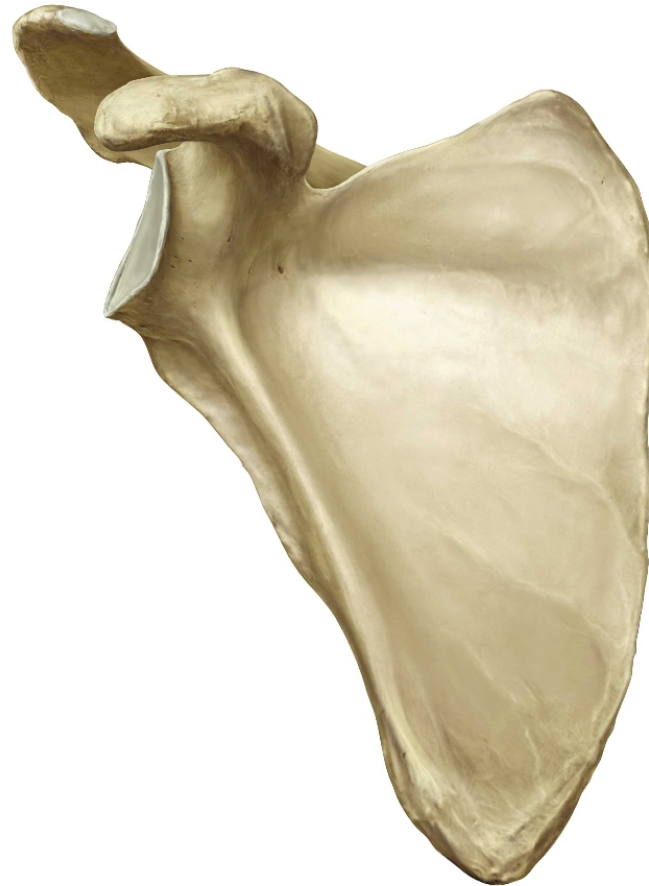Clavicle.

Right clavicle. Inferior view.



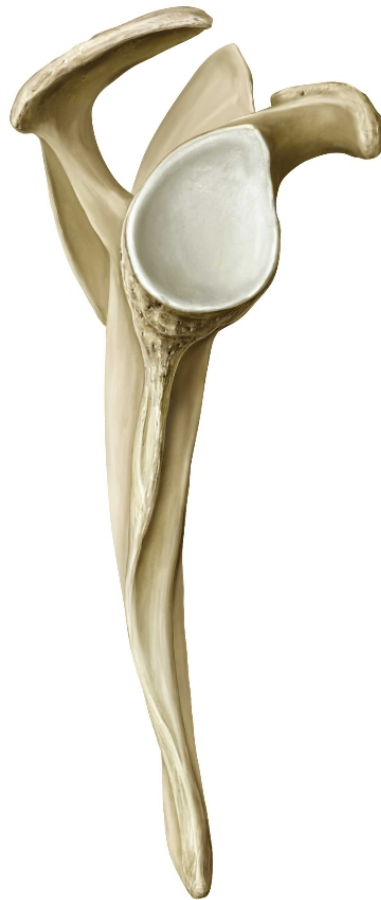Scapula.

Right scapula. Anterior view.



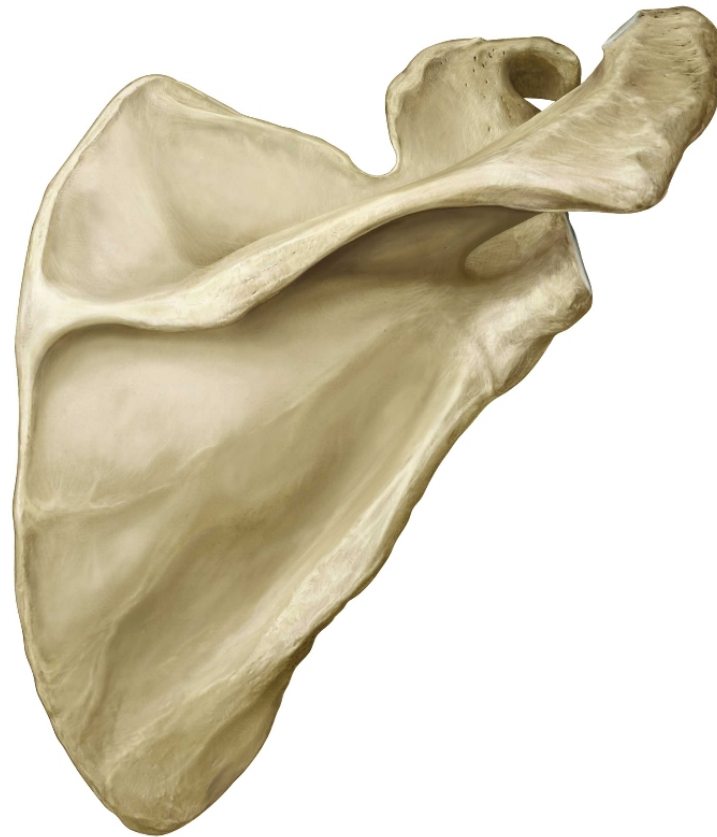
Scapula.

Right scapula. Right lateral view.

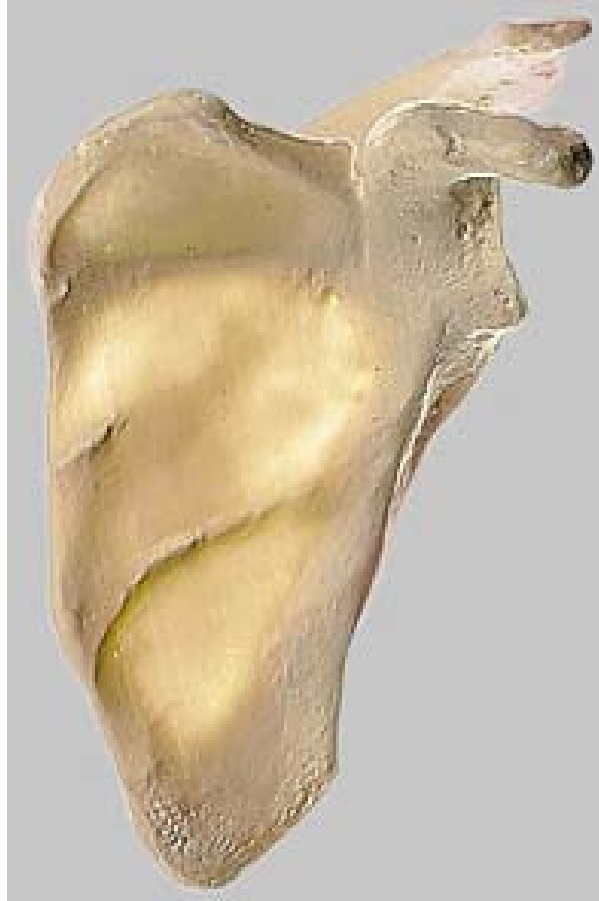

Scapula.

Right scapula. Posterior view.



Scapula



Humerus.

Right humerus. Anterior view.

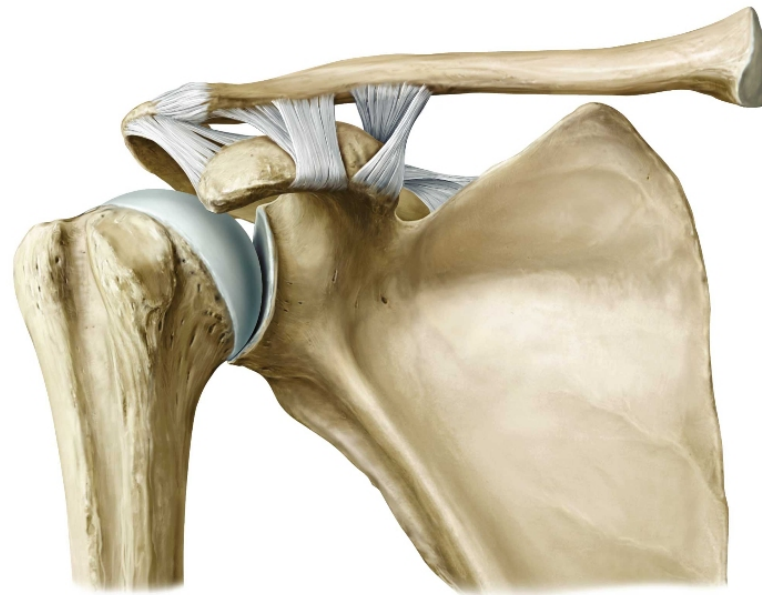


Humerus.

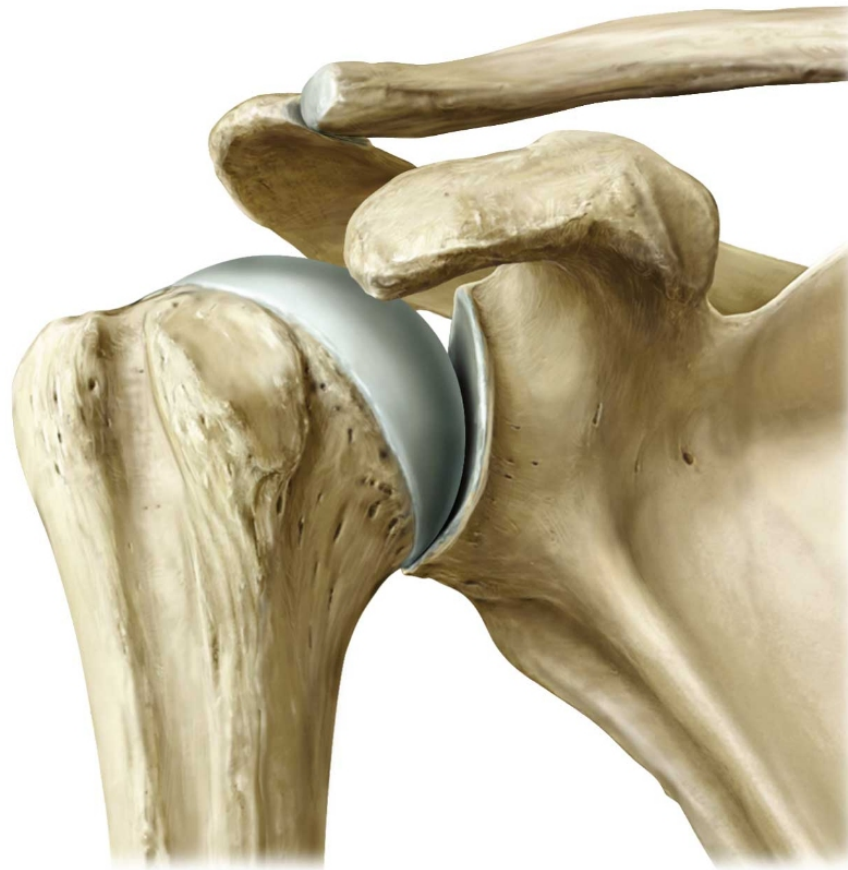Right humerus. Posterior view.



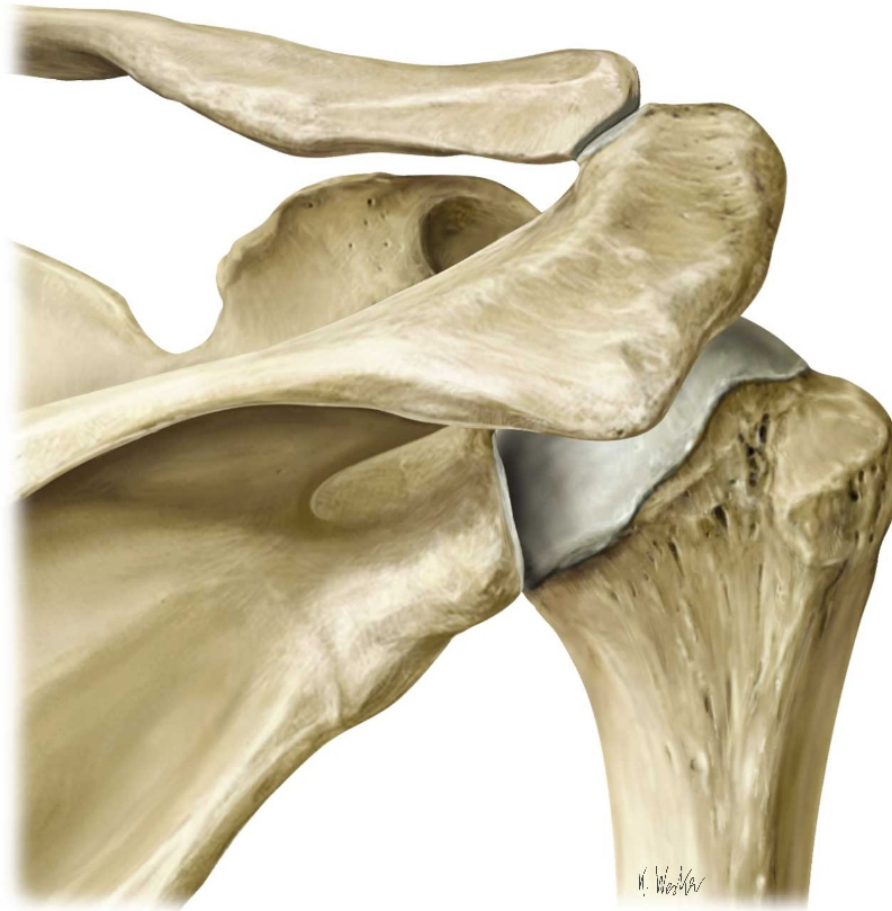
Acromioclavicular joint. Anterior view.



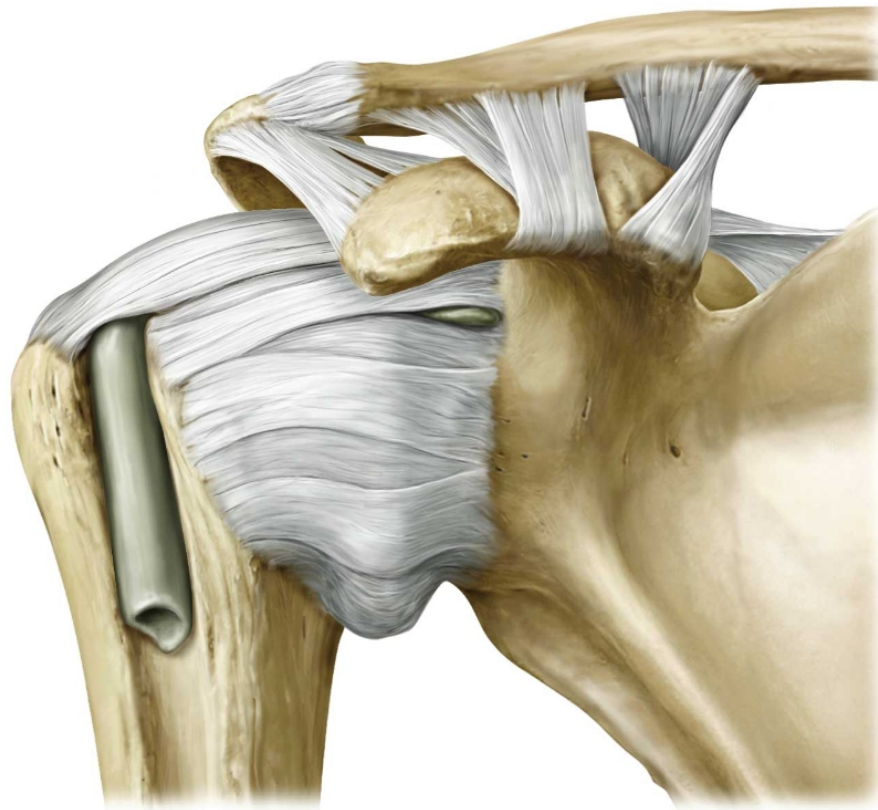
**Glenohumeral joint: Bony elements.
Right shoulder. Anterior view.**



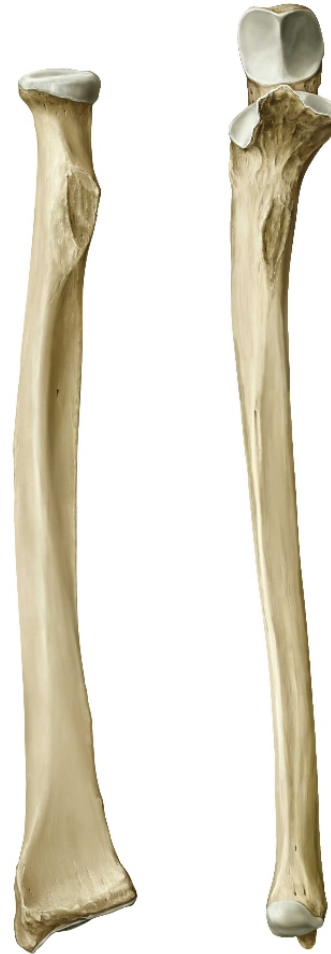**Glenohumeral joint: Bony elements.
Right shoulder. Posterior view.**



**Glenohumeral joint: Capsule and ligaments.
Right shoulder. Anterior view.**



**Radius and ulna. Right forearm.
Anterior view.**



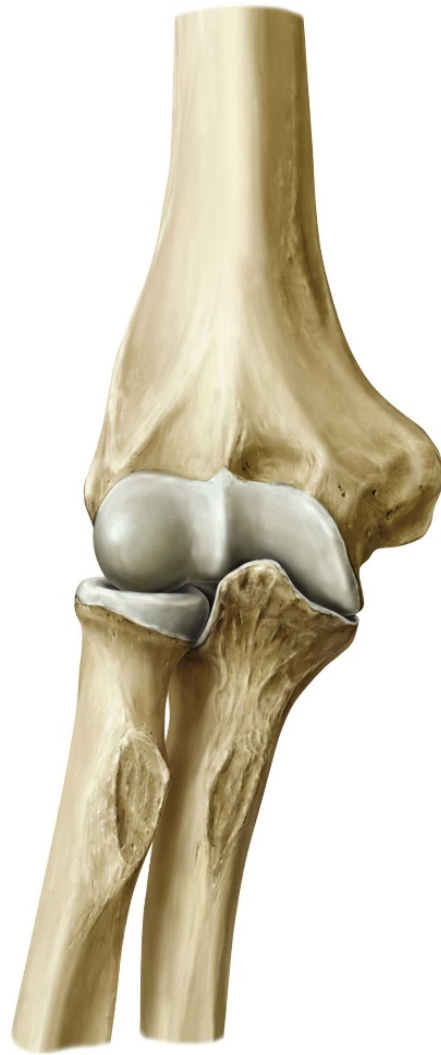Radius and ulna. Right forearm. Anterosuperior view.



Radius and ulna



**Elbow (cubital) joint. Right limb.
Anterior view.**



**Elbow (cubital) joint. Right limb.
Posterior view.**

